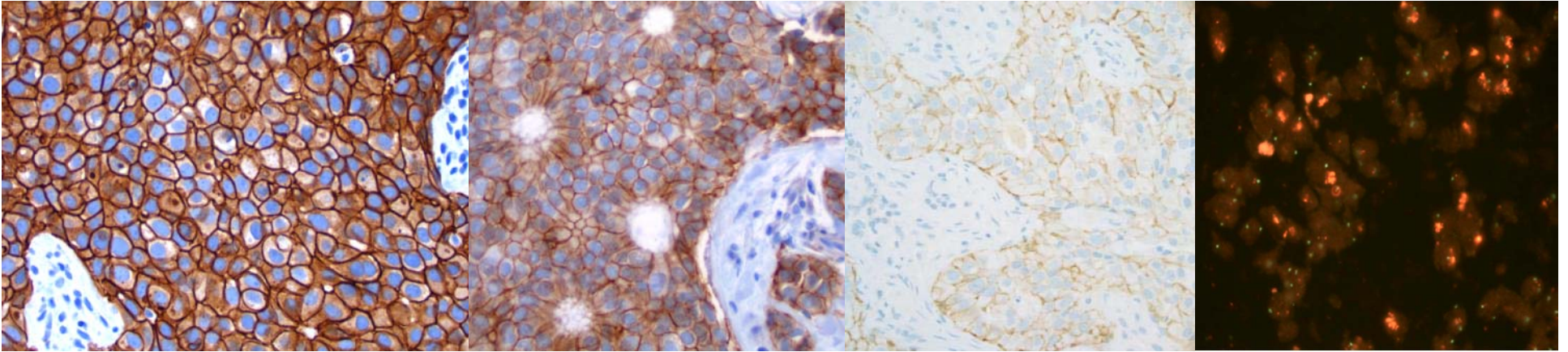

Challenges in Breast Cancer Predictive Marker Interpretation

Kimberly H Allison, MD
Associate Professor of Pathology
Specialist in Breast Pathology
Stanford University Medical Center
allisonk@stanford.edu

Roadmap

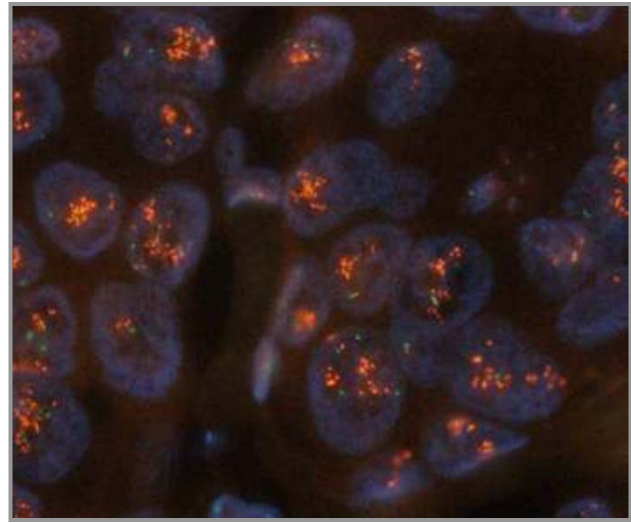
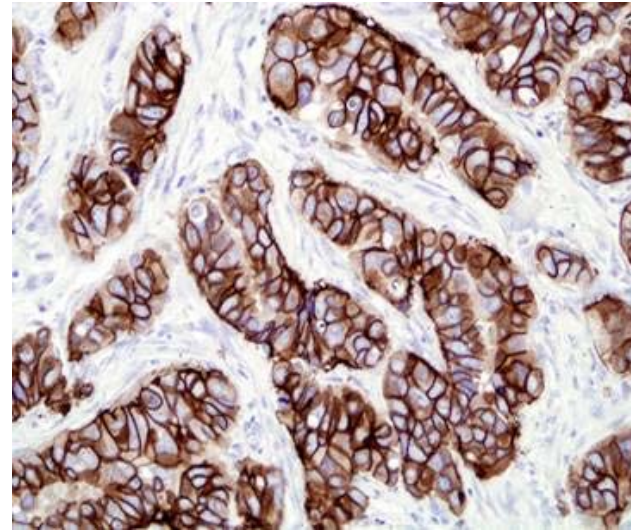
1. Mini-course on HER2 testing (2013 CAP/ASCO Guidelines Update) with test cases
2. Using a series of cases work through challenging cases involving hormone receptor, HER2, Ki67 and Oncotype results :
 - Recognizing and explaining discordant results

Why Test for HER2?

- HER2 positive cancers have:
 - Aggressive biology/worse prognosis (without therapy)
 - Frequent need for chemotherapy (often includes anthracyclines)
 - Frequent benefit from HER2 targeted therapies
 - Reduces recurrences by 50% and mortality by 33%
- Testing is required by CAP/ASCO on all newly diagnosed breast cancers and recurrences/mets
- Clinical trials eligibility can be dependent on HER2 status (including 1+ or 2+ results)

How do we test for HER2?

- Protein Over-Expression: Immunohistochemistry (IHC)
- Gene Amplification: In Situ Hybridization
 - Fluorescence In Situ Hybridization (FISH)
 - Other ISH bright field tests (CISH, SISH, DISH, etc)



Bright-field ISH

- For SISH/CISH/DISH – compare with normal cells and for borderline cases seek expert opinion
- Preferentially use an FDA approved assay or document validation
- Will NOT be covered

How do we test for HER2?

How does your practice test for HER2?

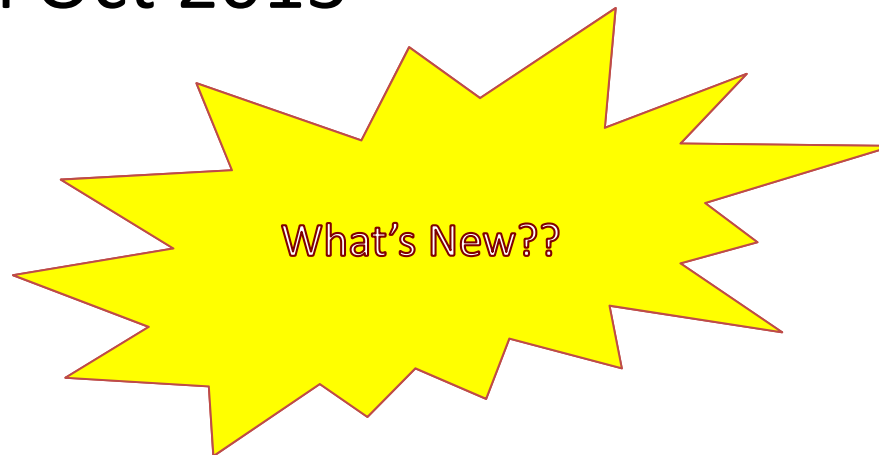- A. IHC first with reflex FISH testing on equivocal cases only
- B. Dual testing (IHC and FISH on all cases)
- C. FISH testing first with reflex IHC on FISH equivocal cases only
- D. Other ISH testing (CISH, DISH or SISH, etc)
- E. Other

Recommendations for Human Epidermal Growth Factor Receptor 2 Testing in Breast Cancer

American Society of Clinical Oncology/College of American Pathologists
Clinical Practice Guideline Update

Antonio C. Wolff, M. Elizabeth H. Hammond*, David G. Hicks*, Mitch Dowsett*, Lisa M. McShane*, Kimberly H. Allison, Donald C. Allred, John M.S. Bartlett, Michael Bilous, Patrick Fitzgibbons, Wedad Hanna, Robert B. Jenkins, Pamela B. Mangu, Soonmyung Paik, Edith A. Perez, Michael F. Press, Patricia A. Spears, Gail H. Vance, Giuseppe Viale, and Daniel F. Hayes**

- New CAP/ASCO HER2 testing guidelines published in Oct 2013



ASCO/CAP HER2 Testing Guideline Update—Wolff et al

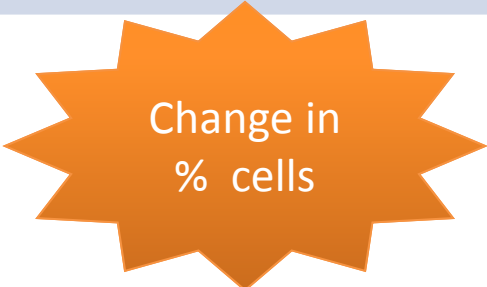
2013 Guidelines: Who to test

Topic	2007 Recommendations	2013 Recommendations
Specimens to be tested	All primary breast cancers and metastases should have at least one HER2 test performed	All newly diagnosed patients with breast cancer must have a HER2 test performed. Patients who then develop metastatic disease must have a HER2 test performed in a metastatic site if available.

Emphasis on retesting new metastases =
estimated that 10-15% change HER2 status

2013 Guidelines: What is a HER2 IHC positive result?

2007 Recommendations	2013 Recommendations
IHC Positive: 3+ by IHC (uniform intense membrane staining of >30%)	IHC Positive: 3+ by IHC (circumferential membrane staining that is complete, intense*+)



Change in
% cells

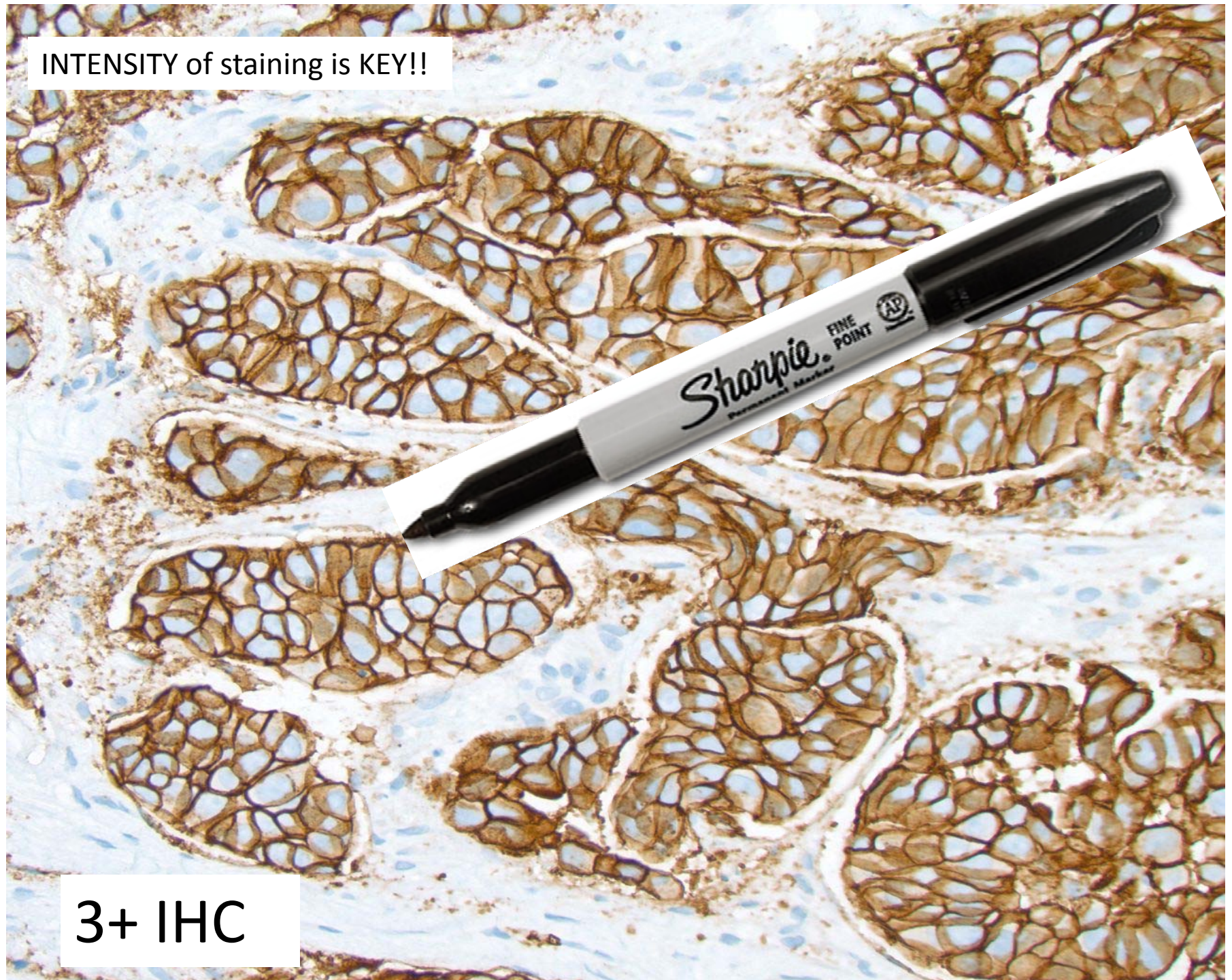
*observed in a homogeneous and contiguous population and within >10% of the invasive tumor cells
+Readily appreciated using a low power objective

NEW: Guidelines recommend reporting what % of cells are 3+ positive in cases reported as positive

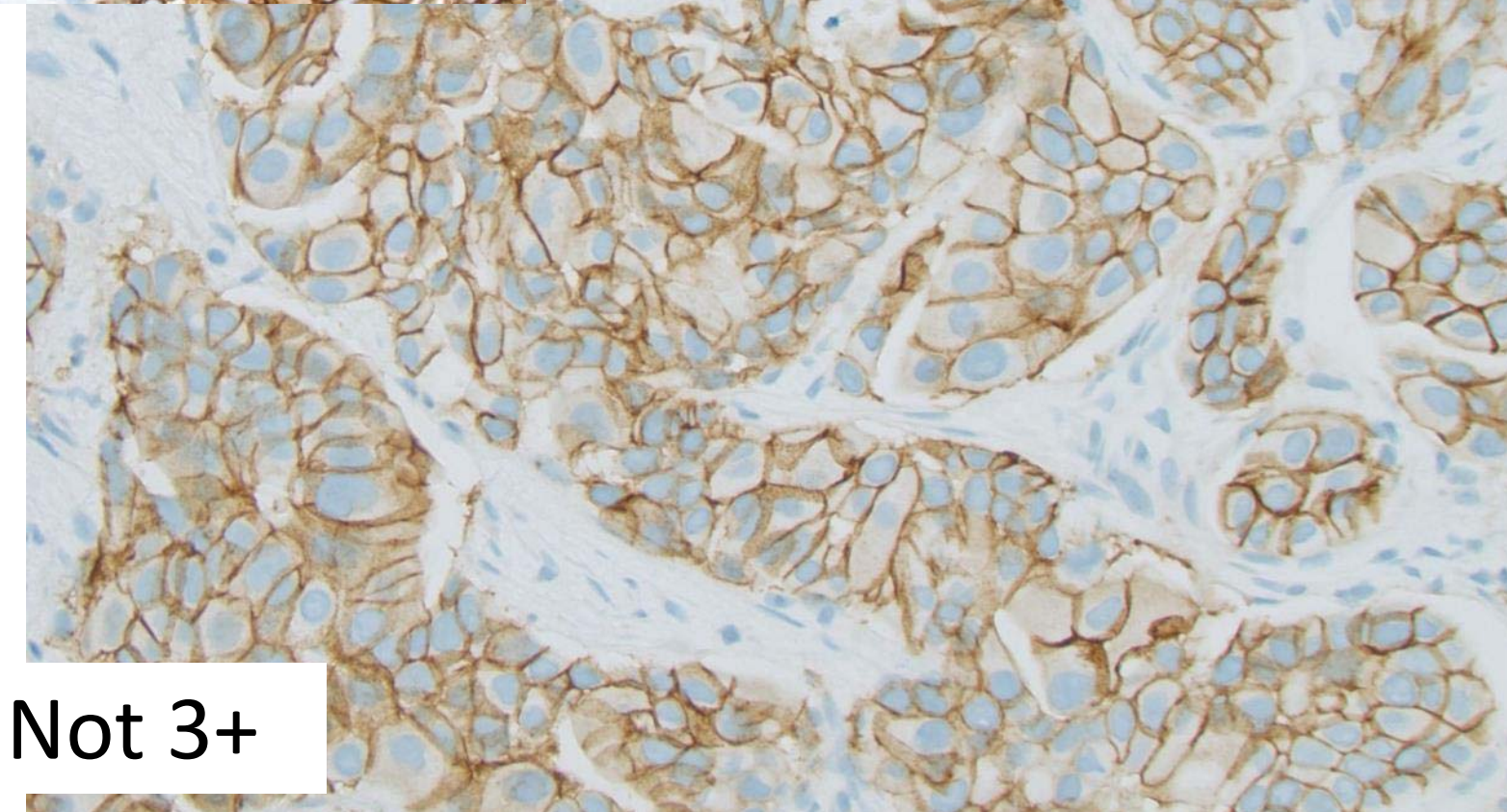
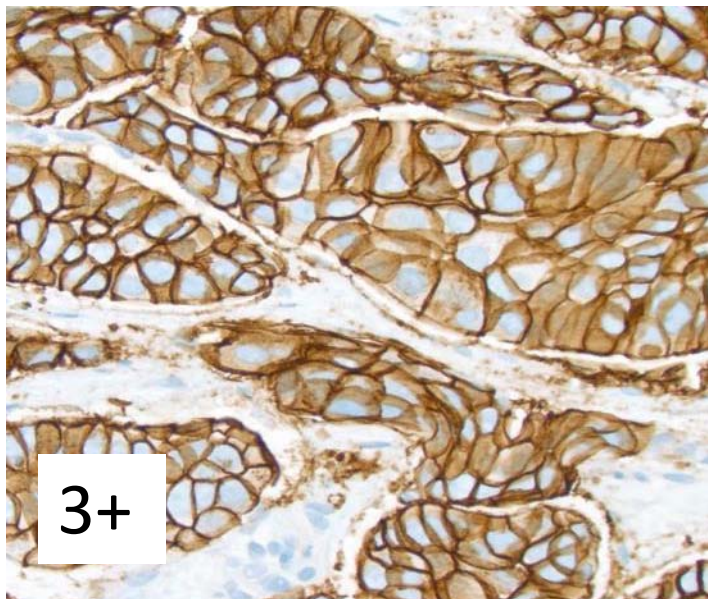
Classically HER2 positive cancers are UNIFORMLY 3+ (>95% of cells)

Advice: Don't perseverate on percentage – usually all or none! If in doubt, call it 2+

INTENSITY of staining is KEY!!



3+ IHC



2013 Guidelines: What is IHC Equivocal?

2007 Recommendations	2013 Recommendations
IHC Equivocal: 2+ by IHC	IHC Positive: 2+ by IHC based on: Circumferential membrane staining that is incomplete and/ <u>or</u> weak/moderate* and within >10% of the invasive tumor cells+ or Complete and circumferential membrane staining that is intense and within \leq 10% of the invasive tumor cells+

*observed in a homogeneous and contiguous population and within >10% of the invasive tumor cells
+Readily appreciated using a low power objective

2013 Guidelines: What is IHC Negative?

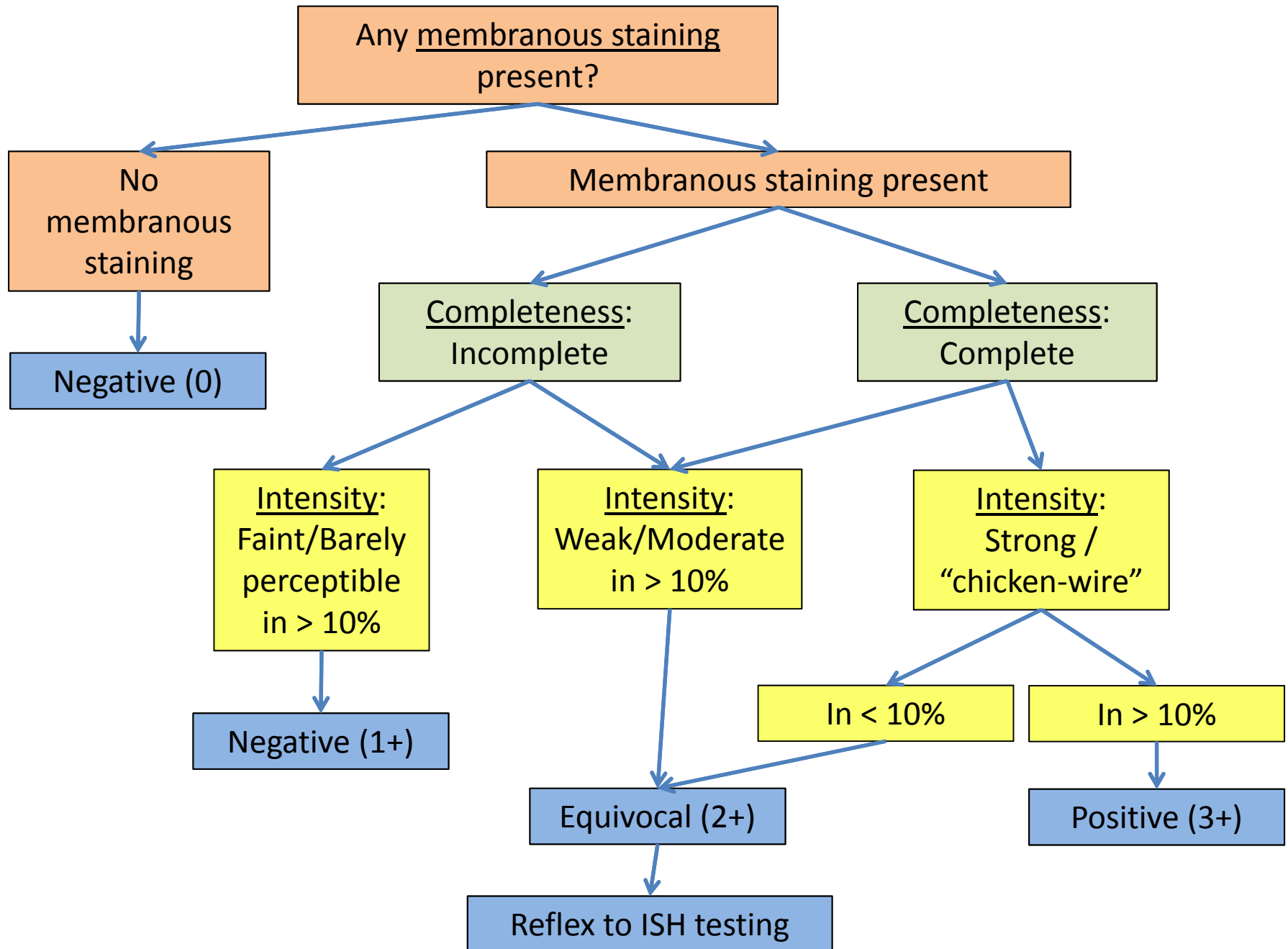
2007 Recommendations	2013 Recommendations
<p>IHC Negative: 0 : No staining</p> <p>1+: Weak incomplete membrane staining in any proportion of tumor cells or weak, complete membrane staining in <10% of cells</p>	<p>IHC Negative: 0 : No staining+ or membrane staining that is incomplete and is faint/barely perceptible and within $\leq 10\%$ of the invasive tumor cells+</p> <p>1+: incomplete membrane staining that is faint/barely perceptible and within $> 10\%$ of the invasive tumor cells</p>



More
detailed
definitions
for 0 and
1+ staining

+Readily appreciated using a low power objective

Evaluation of HER2 IHC staining in invasive breast cancer

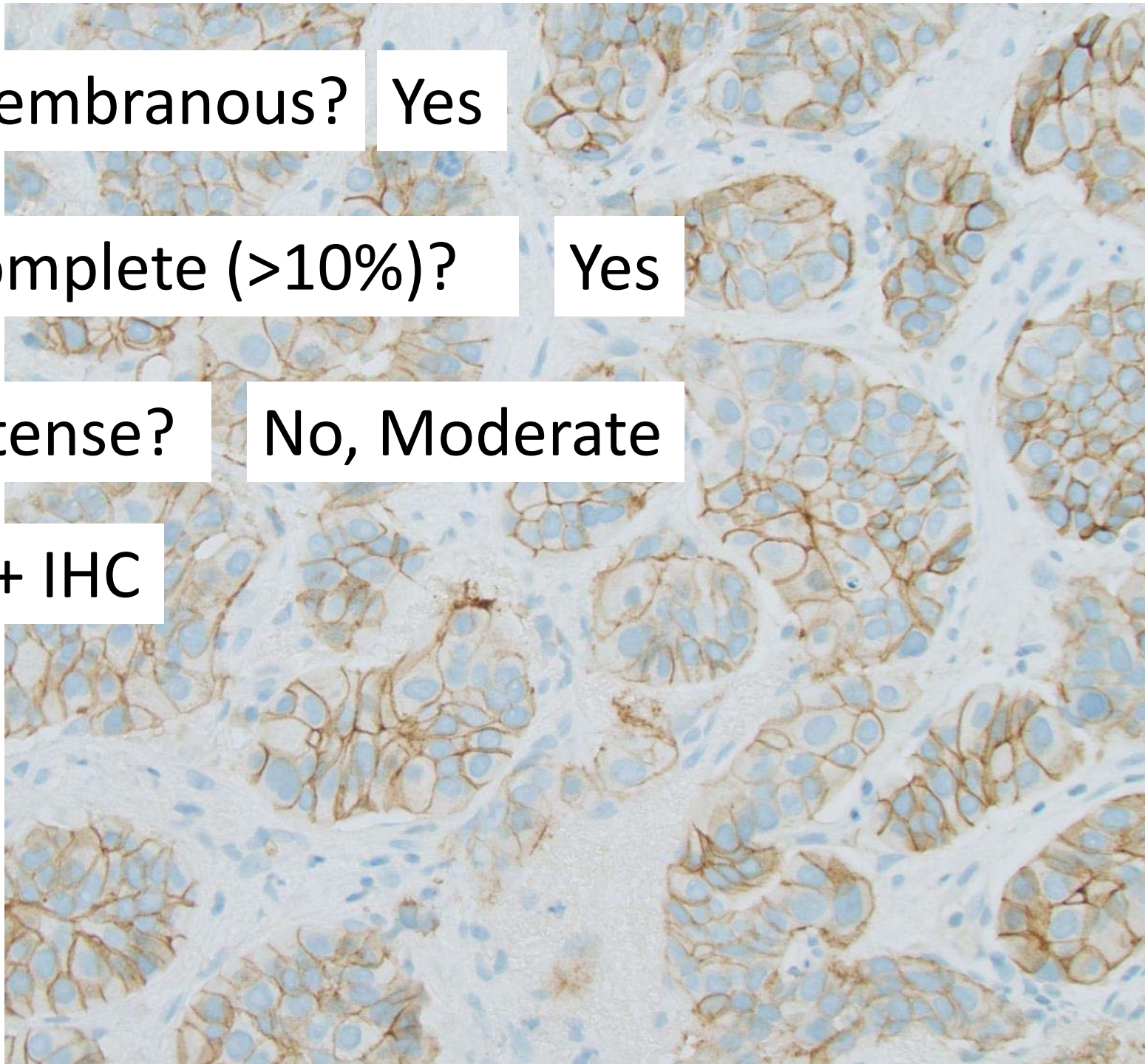


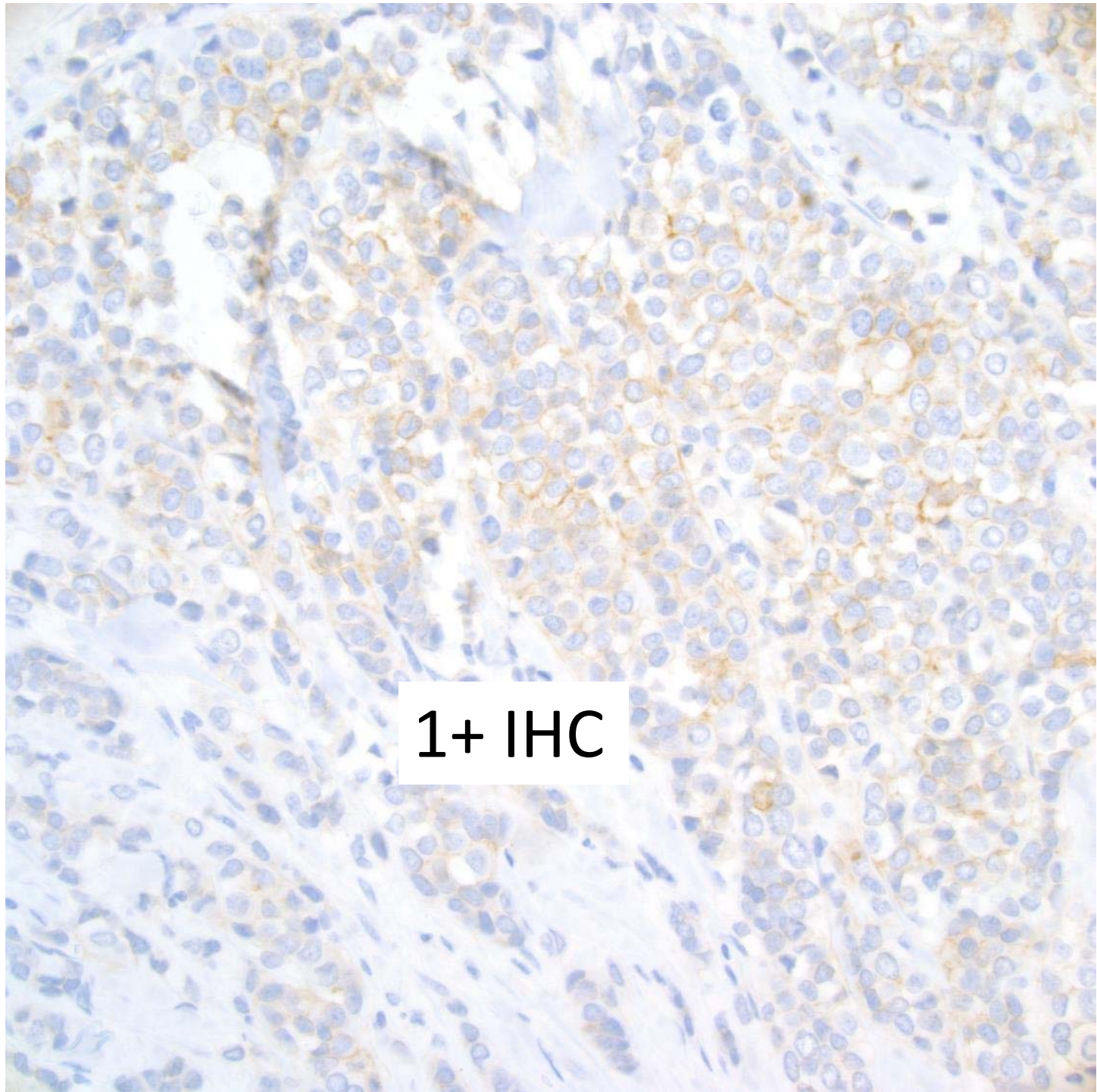
Membranous? Yes

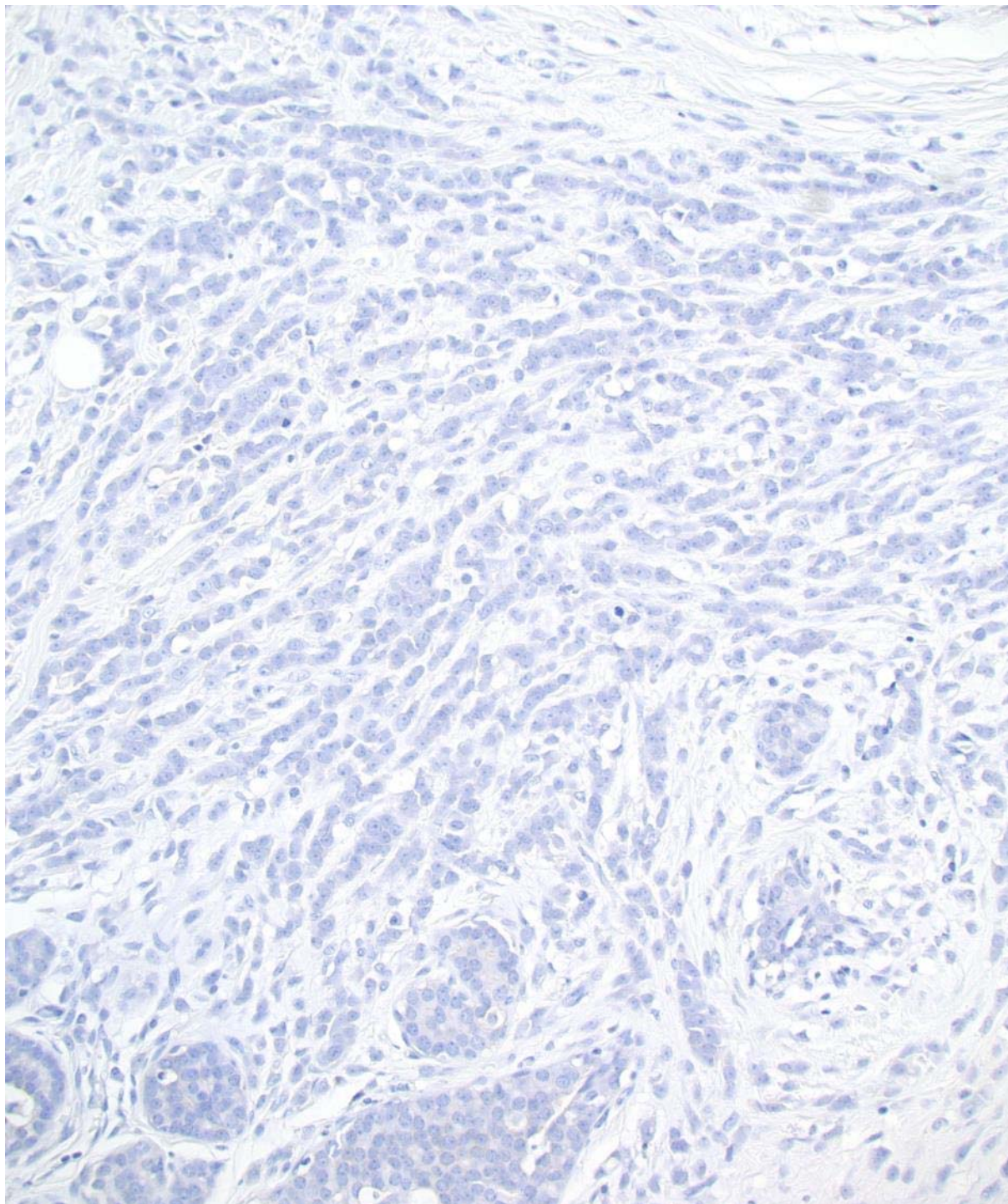
Complete (>10%)? Yes

Intense? No, Moderate

2+ IHC







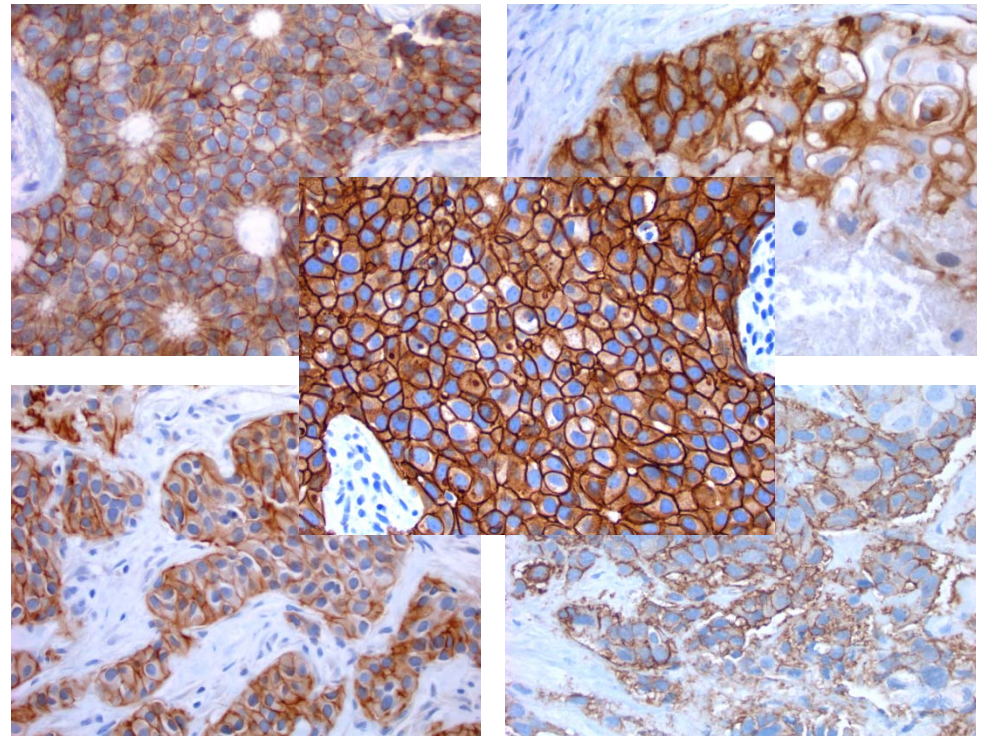
0 IHC

Achieving 95% Cross-Methodological Concordance in HER2 Testing

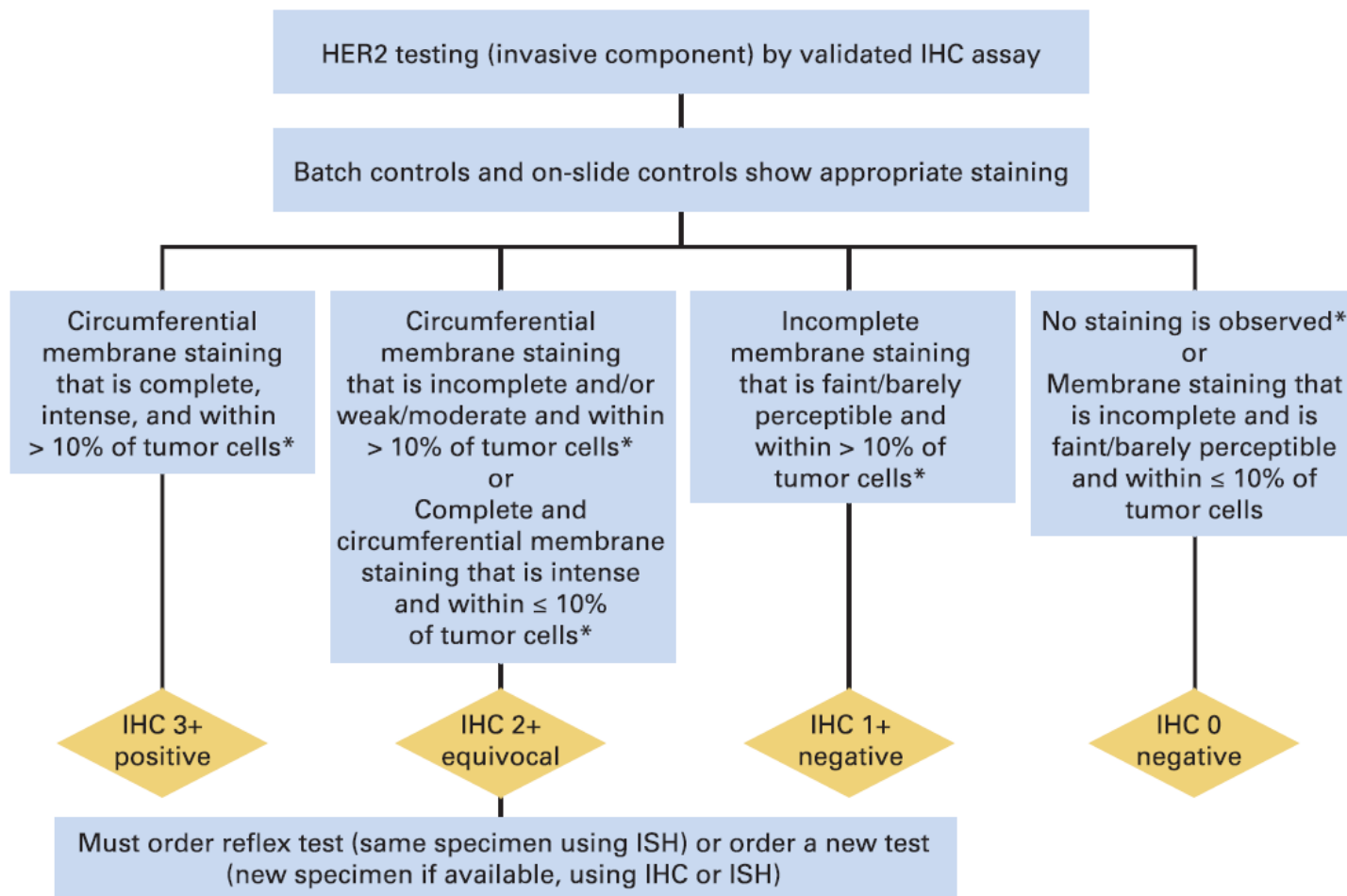
Causes and Implications of Discordant Cases

Erin E. Grimm, MD, Rodney A. Schmidt, MD, PhD, Paul E. Swanson, MD, Suzanne M. Dintzis, MD, PhD, and Kimberly H. Allison, MD

- 697 cases with both IHC and FISH results
- 96% overall concordance
- Most common reason for discordant on review: Over-interpretation of IHC stain intensity



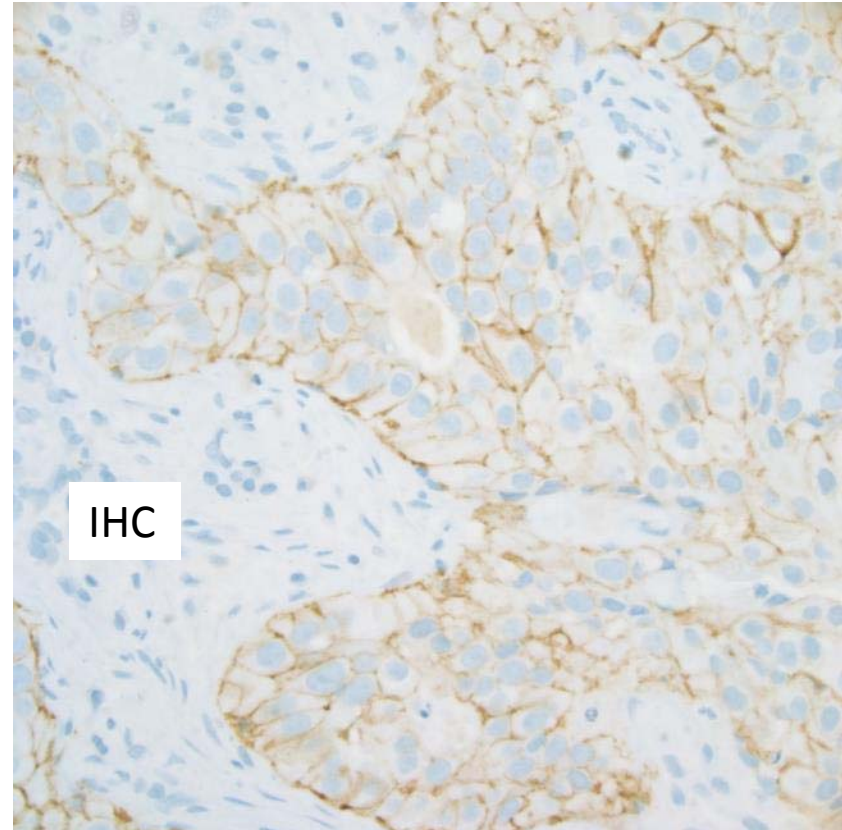
IHC Summary



Test Case 1

42 year old with a diagnosis of invasive mucinous carcinoma. You receive the HER2 IHC and FISH for interpretation. How do you report the case?

- A. IHC 2+ (equivocal), FISH amplified
- B. IHC 3+ (positive), FISH amplified
- C. IHC 2+ (equivocal), FISH equivocal
- D. IHC 1+ (negative), FISH amplified
- E. Repeat the test and review the histology

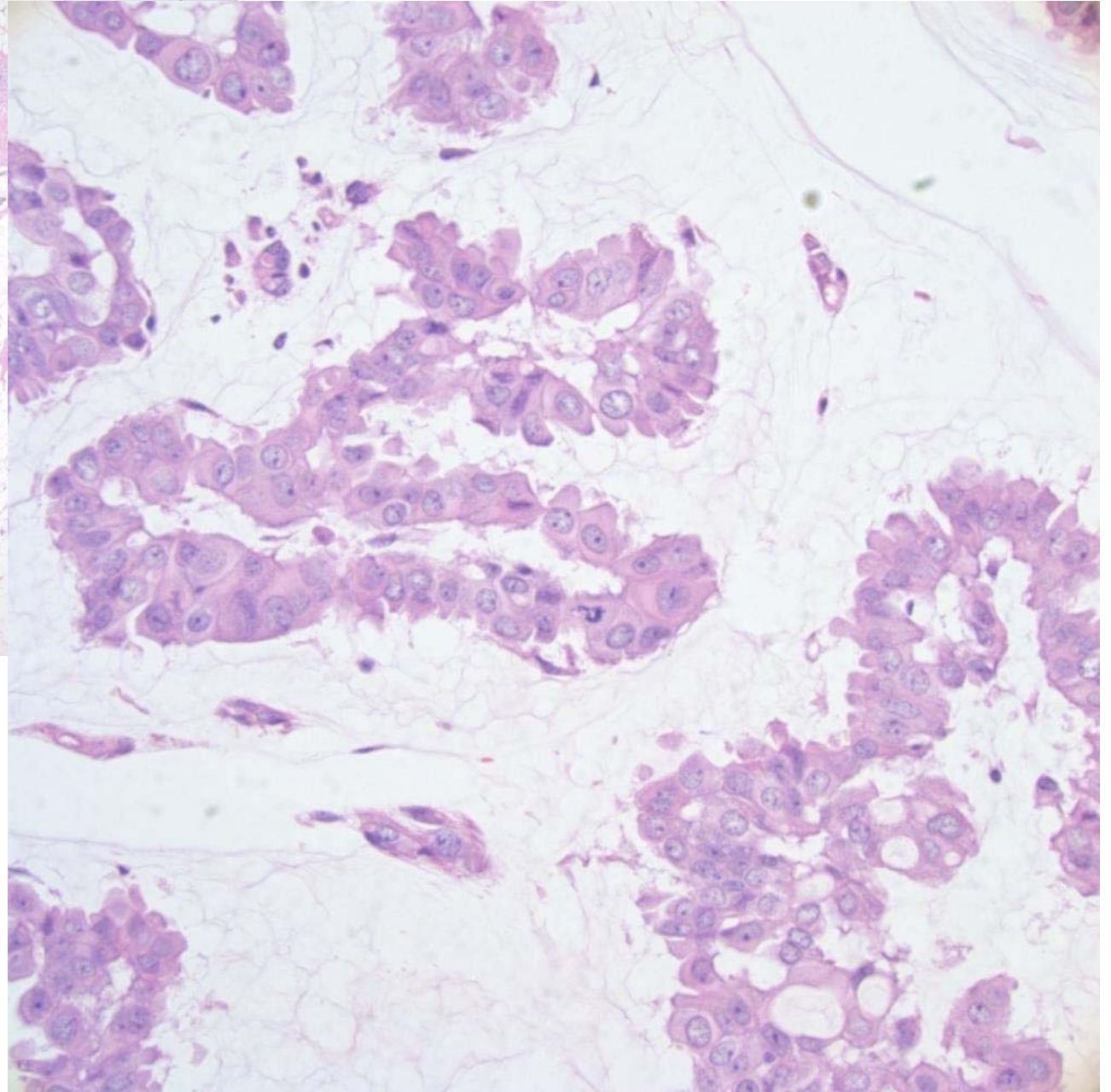
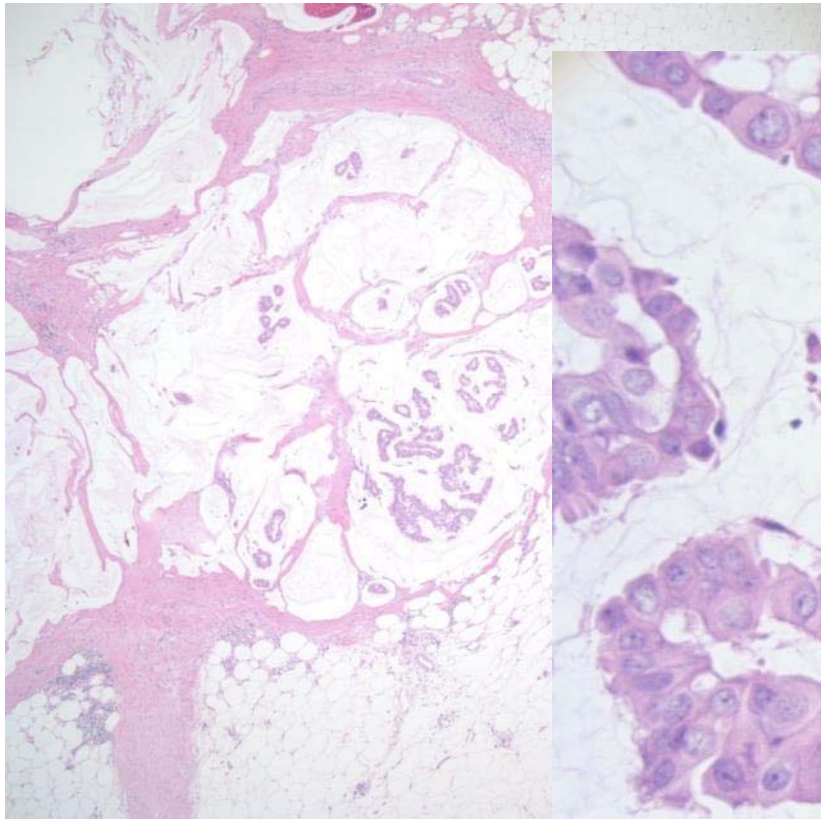


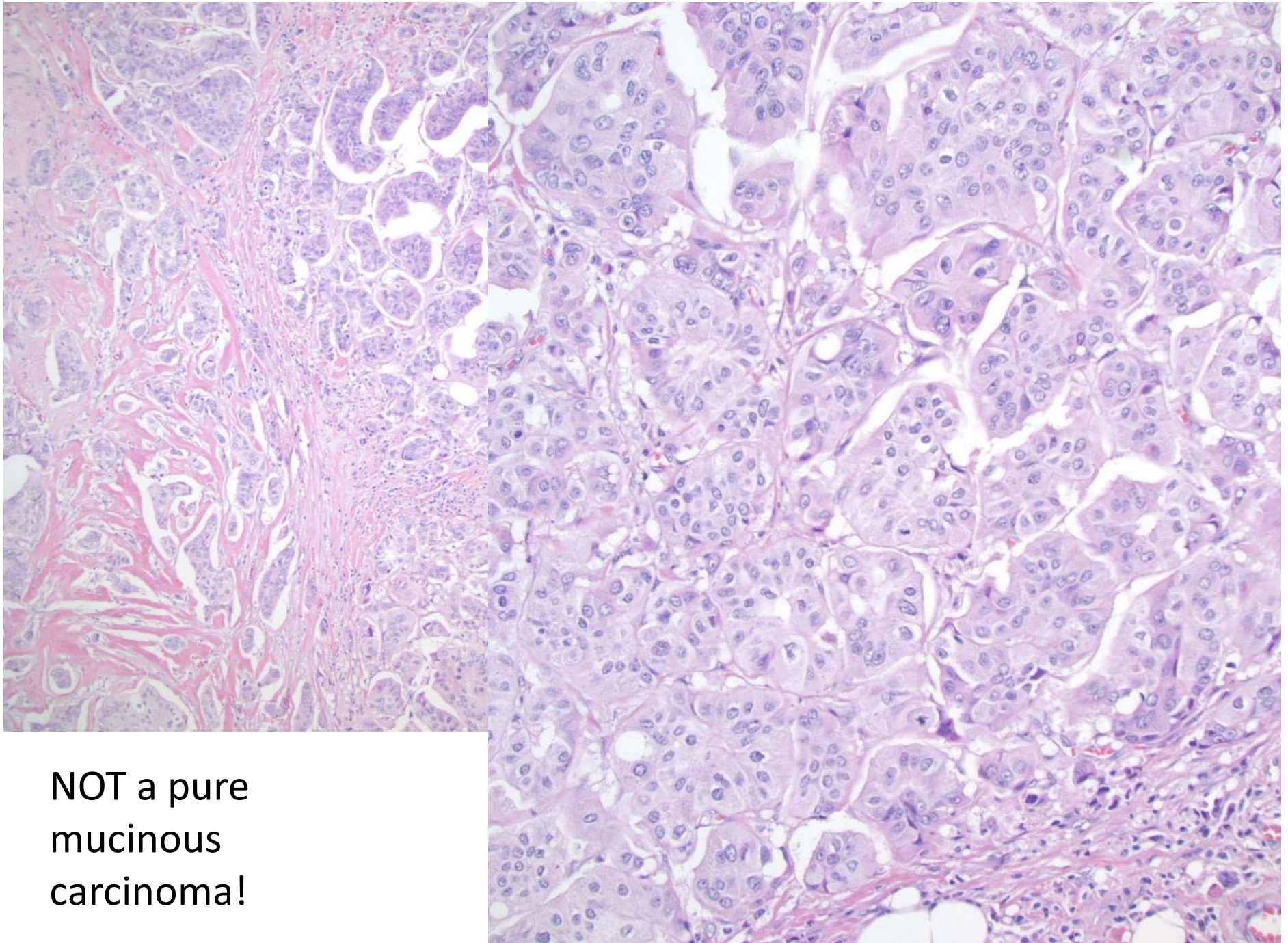
FISH results:

Mean HER2 signals/cell = 8.0

Mean CEP17 signals/cell = 2.2

HER2:CEP17 Ratio = 3.6





NOT a pure
mucinous
carcinoma!

Recognizing Possible Discordant HER2 Testing

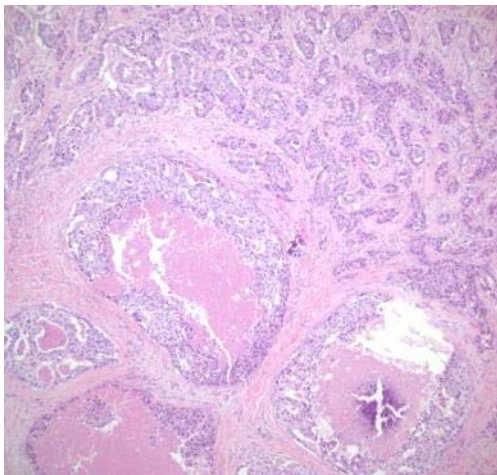
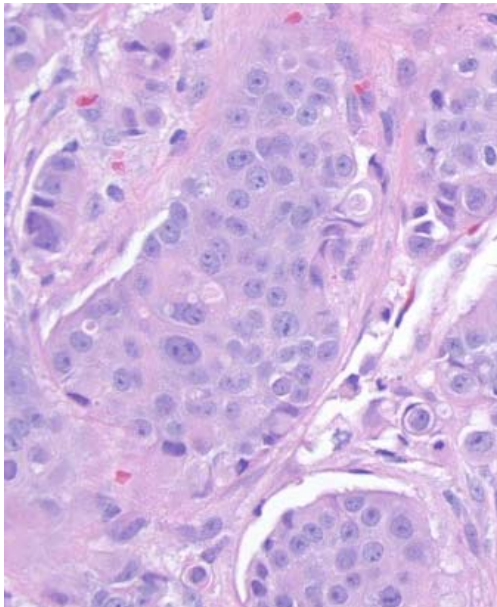
Discordant if HER2 positive and Grade 1 invasive carcinoma of any of the following types:

- Ductal or lobular and ER and PR positive
- Pure Tubular, Mucinous, Cribriform or Adenoid Cystic

Table 2. Histopathologic Features Suggestive of Possible HER2 Test Discordance
Criteria to Consider*
<p>New HER2 test should not be ordered if the following histopathologic findings occur and the initial HER2 test was negative:</p> <p>Histologic grade 1 carcinoma of the following types:</p> <ul style="list-style-type: none"> Infiltrating ductal or lobular carcinoma, ER and PgR positive Tubular (at least 90% pure) Mucinous (at least 90% pure) Cribriform (at least 90% pure) Adenoid cystic carcinoma (90% pure) and often triple negative <p>Similarly, a new HER2 test should be ordered if the following histopathologic findings occur and the initial HER2 test was positive:</p> <p>Histologic grade 1 carcinoma of the following types:</p> <ul style="list-style-type: none"> Infiltrating ductal or lobular carcinoma, ER and PgR positive Tubular (at least 90% pure) Mucinous (at least 90% pure) Cribriform (at least 90% pure) Adenoid cystic carcinoma (90% pure) and often triple negative <p>If the initial HER2 test result in a core needle biopsy specimen of a primary breast cancer is negative, a new HER2 test must be ordered on the excision specimen if one of the following is observed:</p> <ul style="list-style-type: none"> Tumor is grade 3 Amount of invasive tumor in the core biopsy is small Resection specimen contains high-grade carcinoma that is morphologically distinct from that in the core Core biopsy result is equivocal for HER2 after testing by both ISH and IHC There is doubt about the specimen handling of the core biopsy (long ischemic time, short time in fixative, different fixative) or the test is suspected by the pathologist to be negative on the basis of testing error

ASCO/CAP HER2 Testing Guideline Update—Wolff et al

Classic HER2 Positive Cancer Features



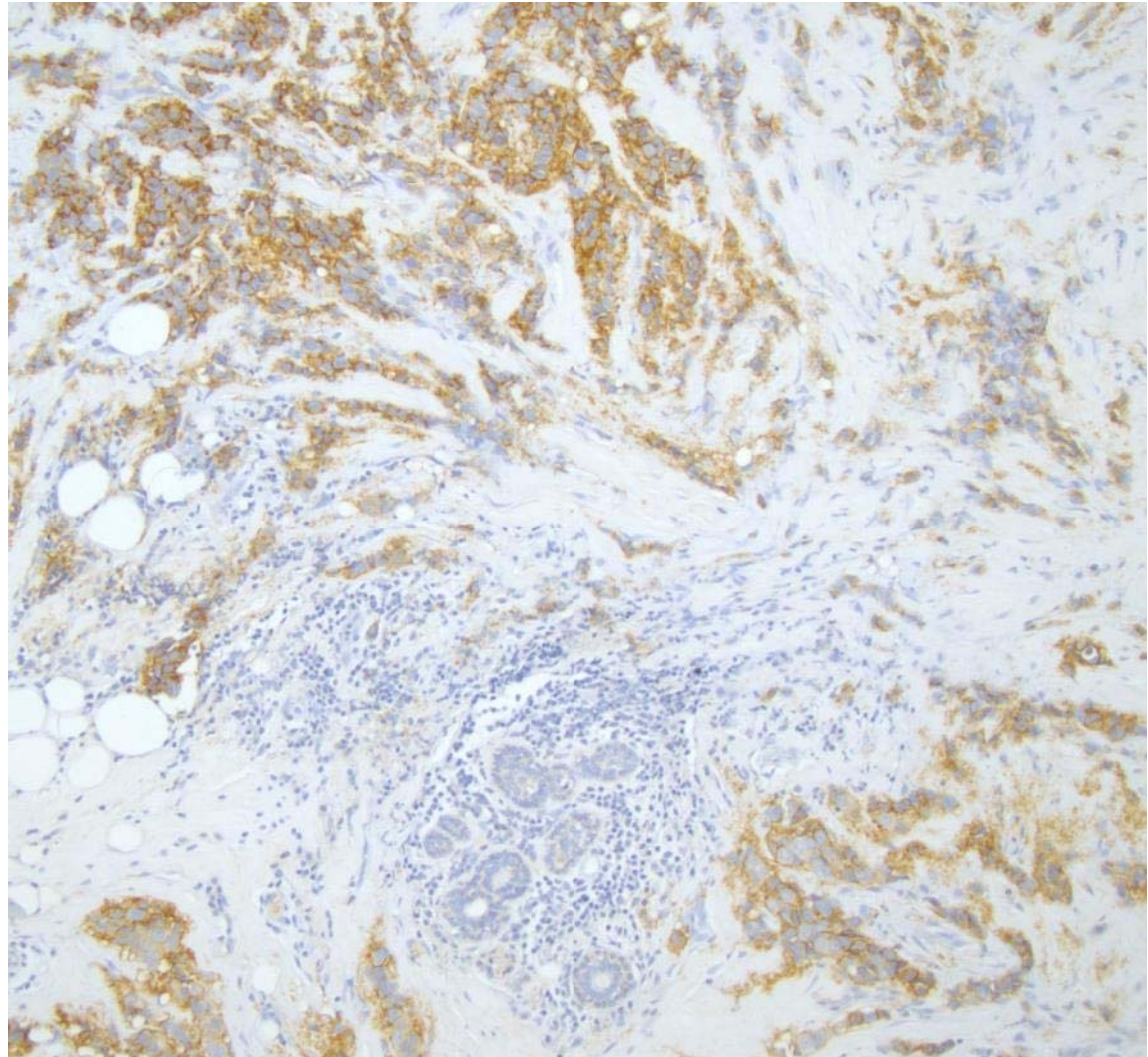
- High grade
- Apocrine-like features (abundant cytoplasm, nucleoli)
- Comedo DCIS
- Frequently ER/PR negative (not always)
- Younger patients
- Higher stage at diagnosis

HER2 Negative on Core Biopsy; When to Retest in the Excision?

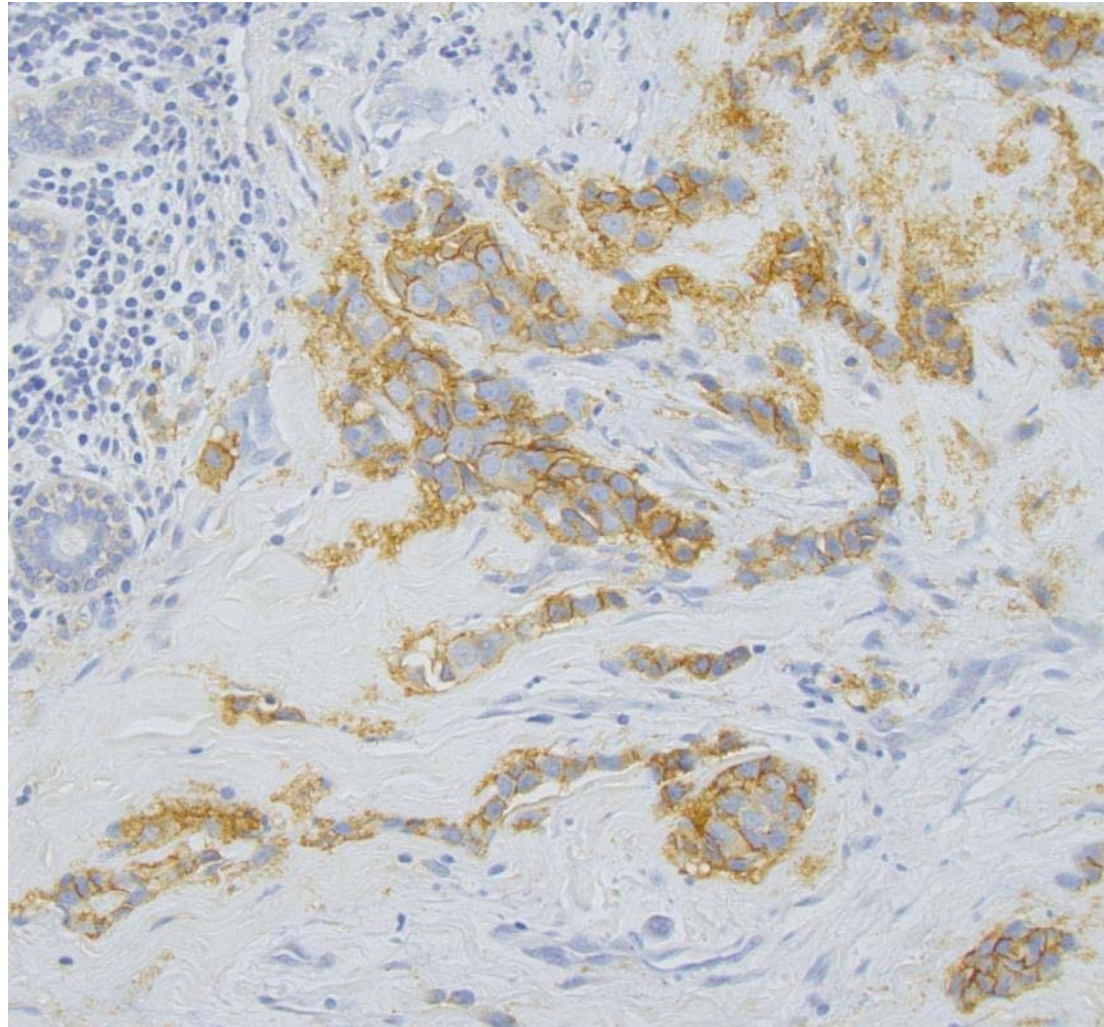
- Tumor is Grade 3
- Amount of invasion in core was small
- Resection has high grade carcinoma that is morphologically distinct from that in core
- Core biopsy result is equivocal for HER2 after both IHC and ISH
- Doubt about specimen handling of core
- Pathologist suspects testing error

Test Case 2

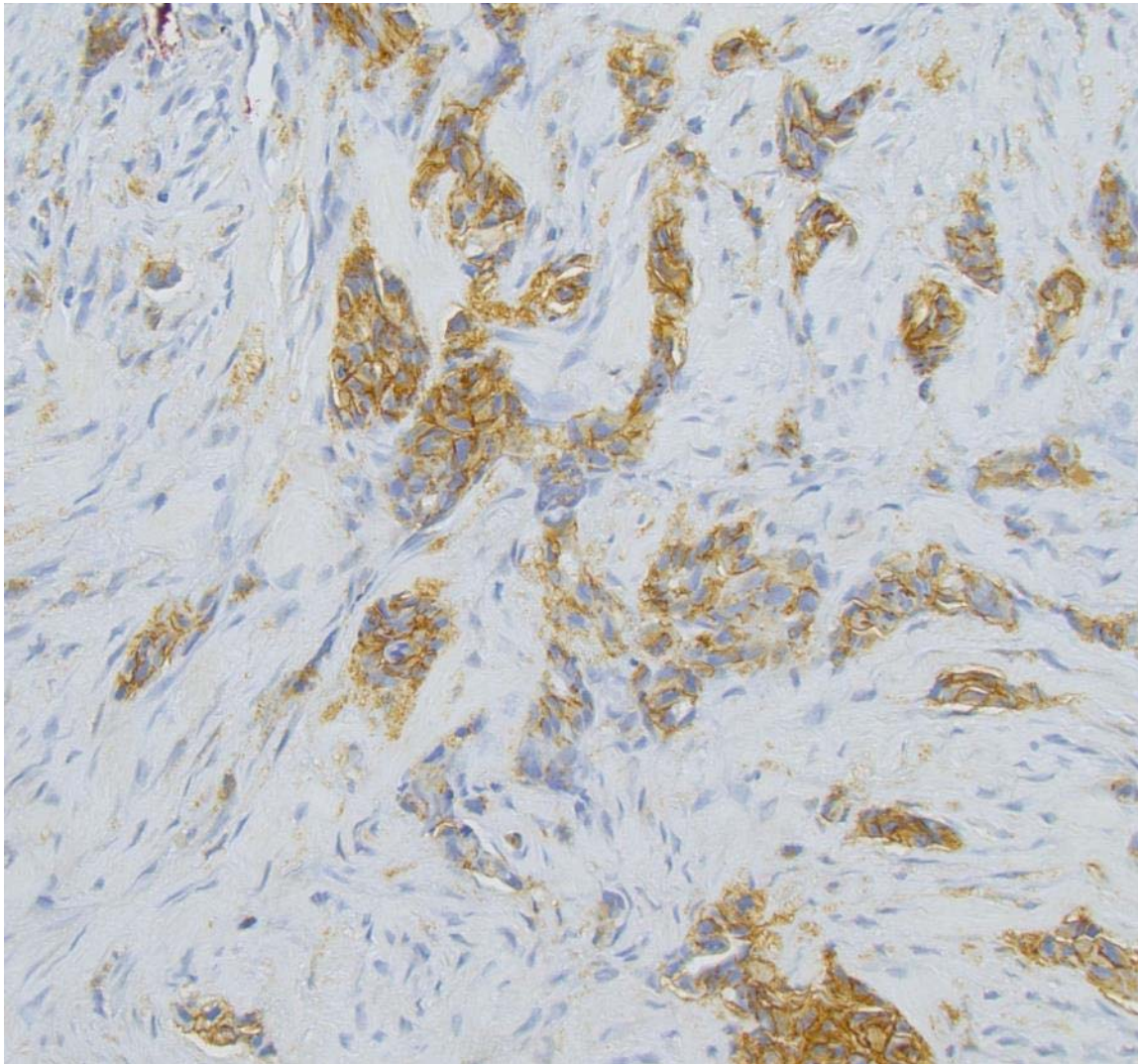
- Nottingham grade 2 invasive ductal carcinoma
- 50 year old woman
- You receive the HER2 IHC stain to interpret



Test Case 2



Test Case 2



- A. 0
- B. 1+
- C. 2+
- D. 3+
- E. Other

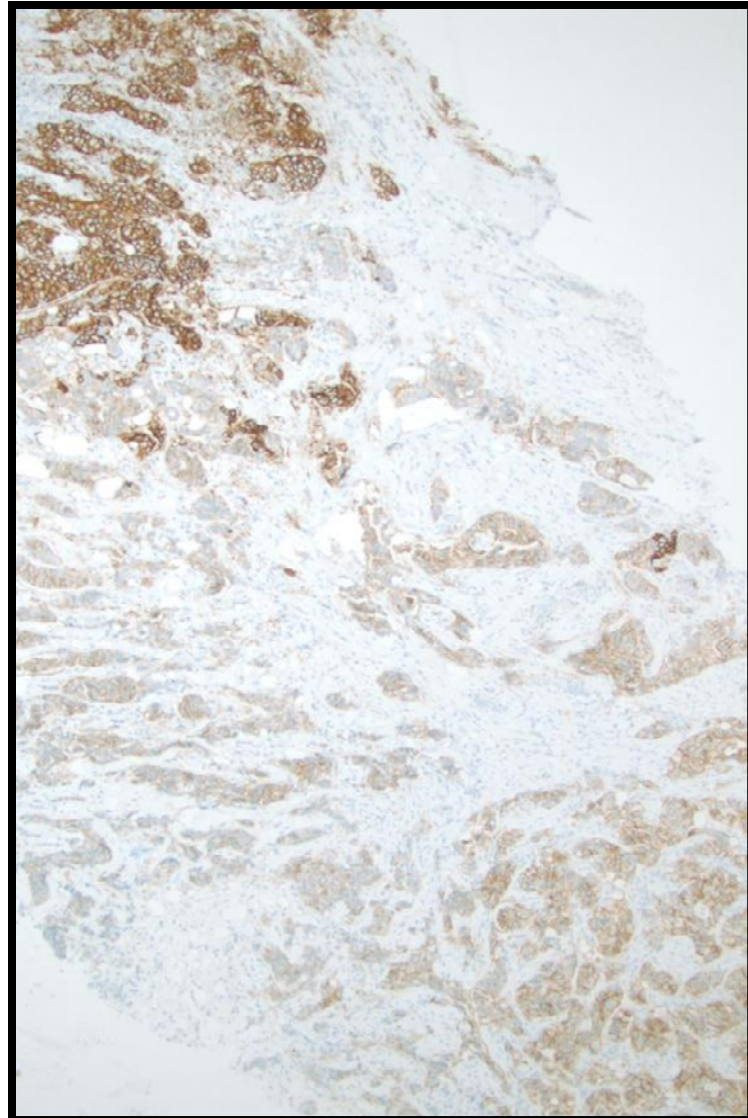
2013 Guidelines: What is HER2 Indeterminate?

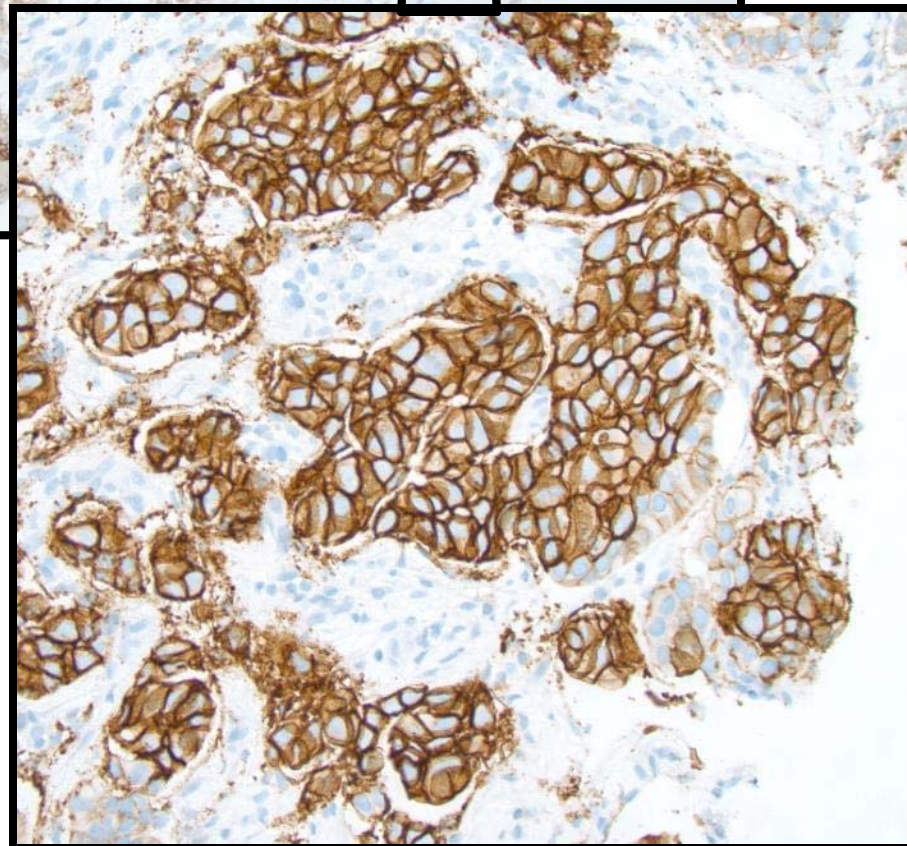
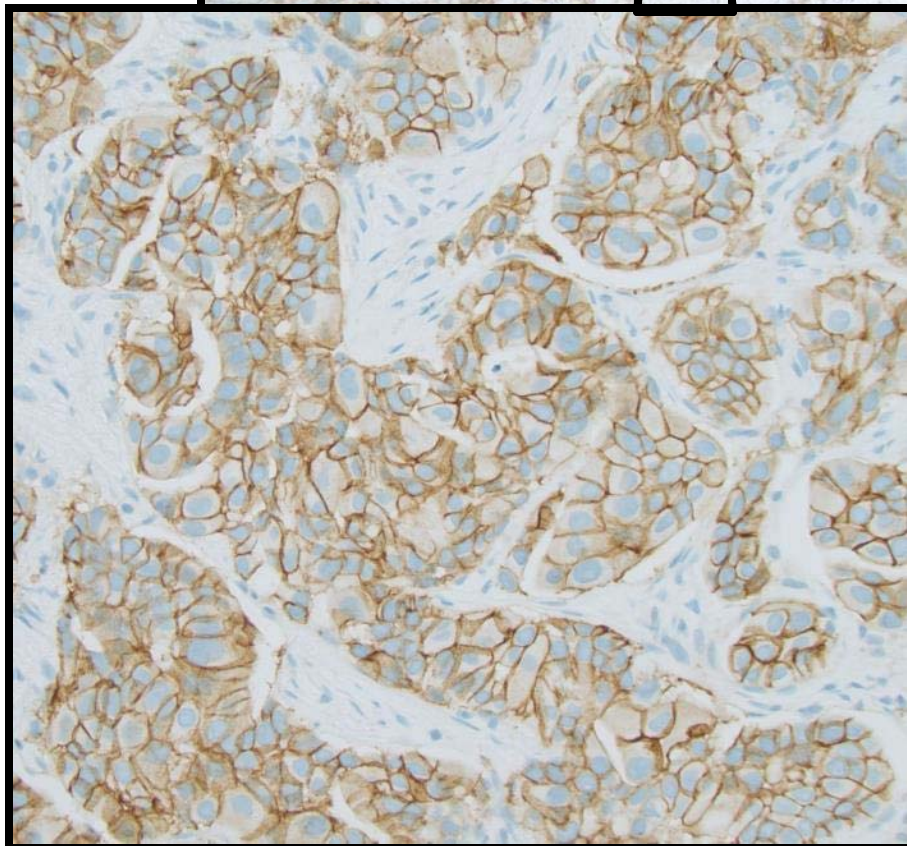
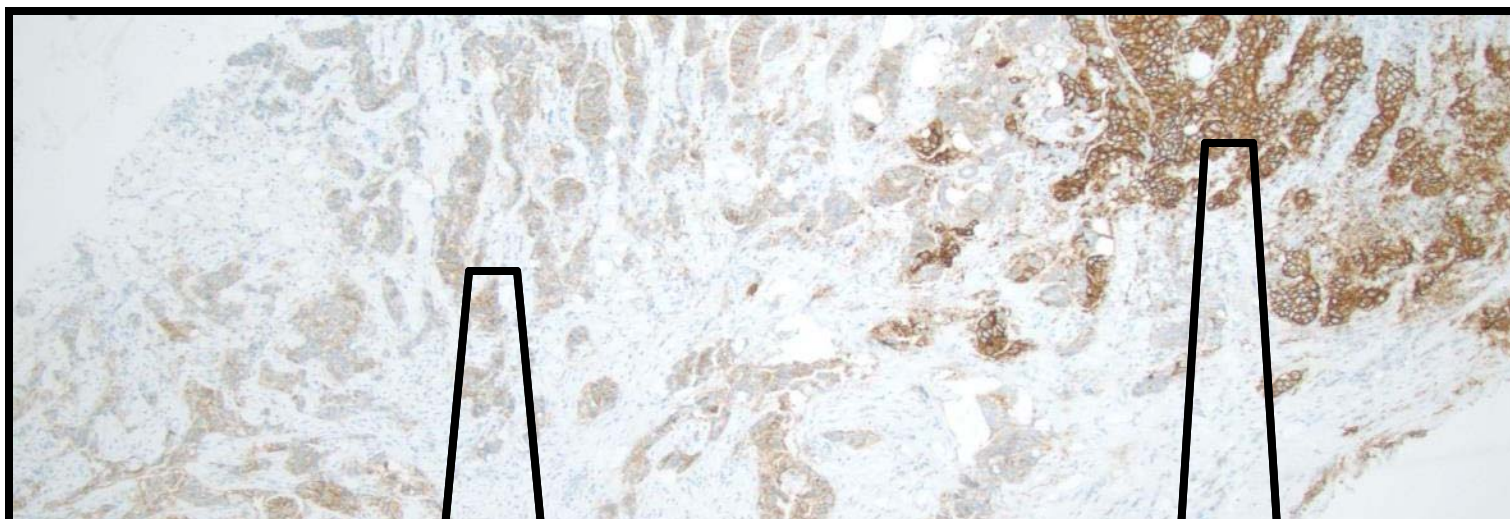
- Inadequate specimen handling
- Artifacts (crush or edge)
- Analytical testing failure
- Controls not as expected
- Unstained slide cut > 6 weeks prior
- For ISH:
 - Not at least 2 areas to count, >25% of signals unscorable/weak, > 10% of signals occur over cytoplasm, nuclear resolution poor, auto-fluorescence strong
- Reason for indeterminate result should be reported
- Another method of testing can be attempted or another sample requested

Cold ischemic time < 1 hour
Formalin fix 6-**72** hours

Test Case 3

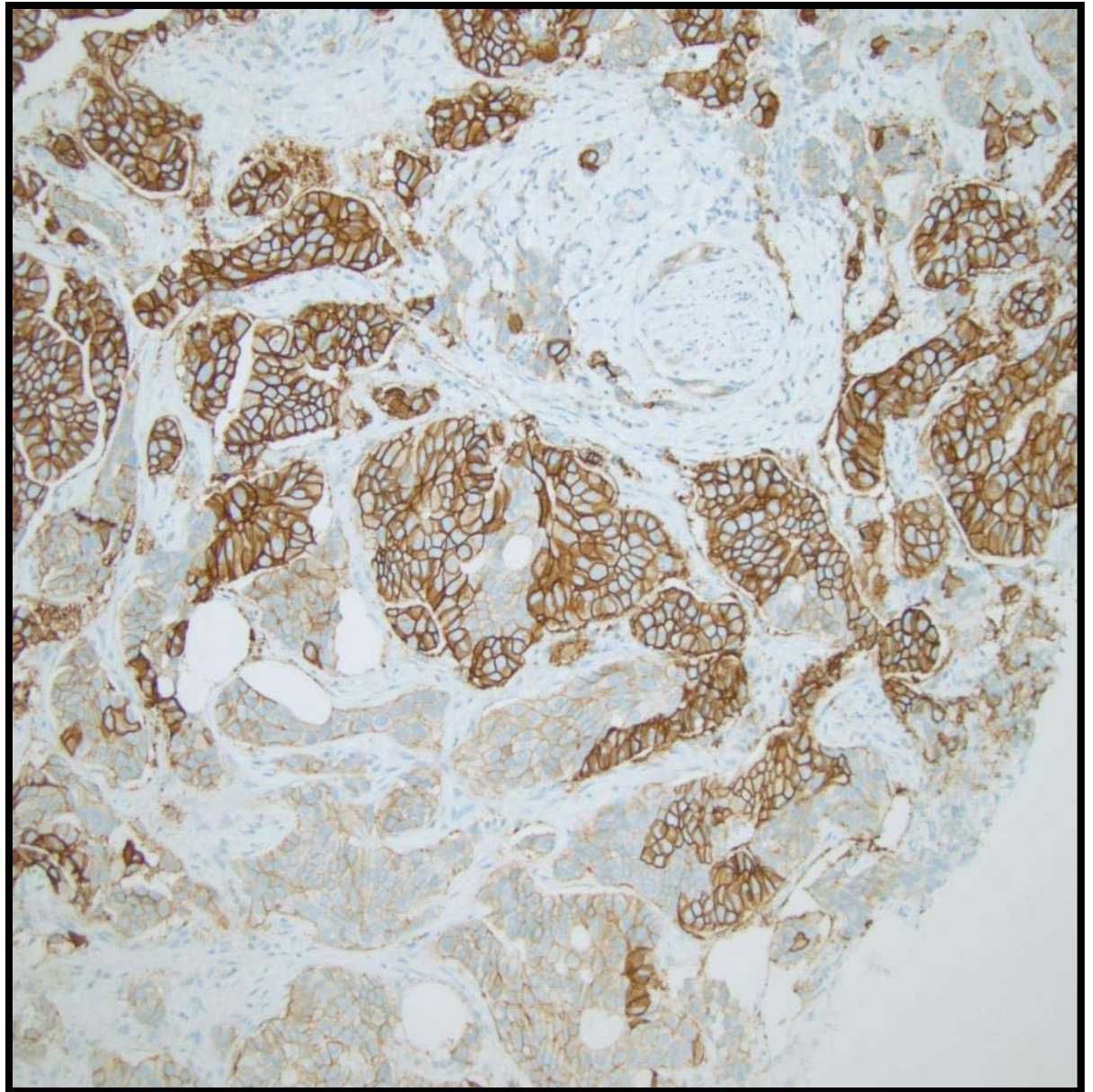
- Nottingham grade 3 invasive ductal carcinoma
- 45 year old woman
- You receive the HER2 IHC to interpret



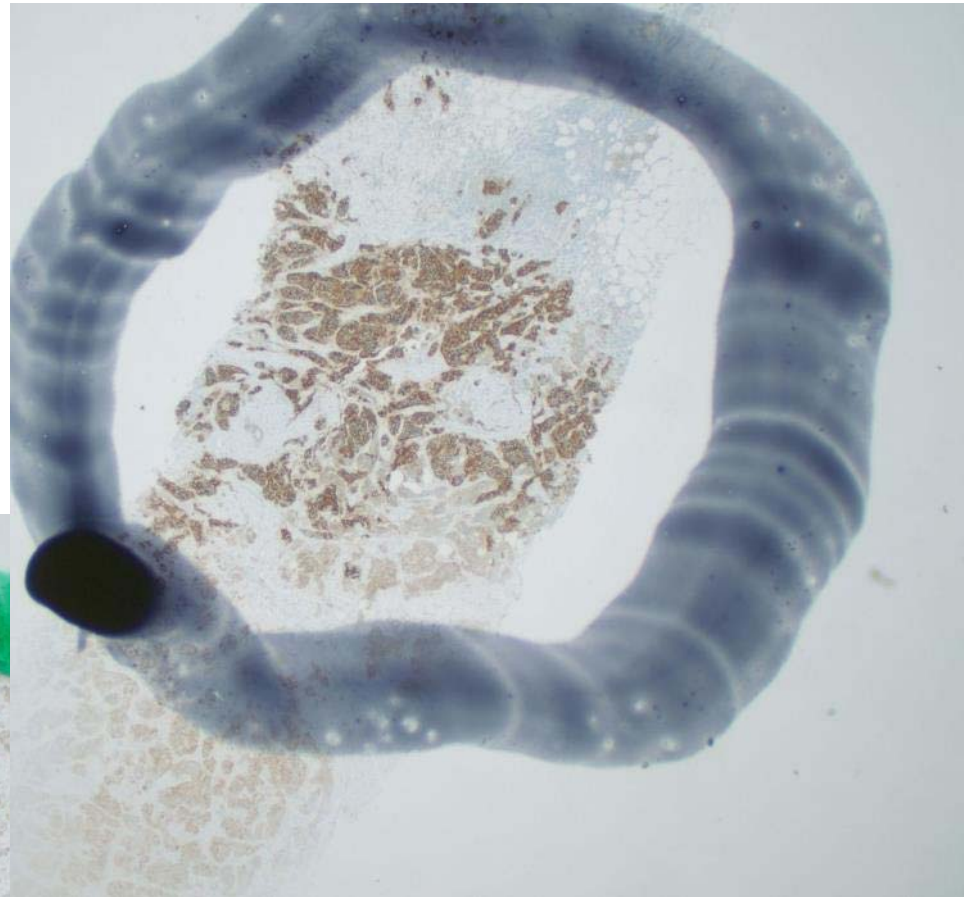
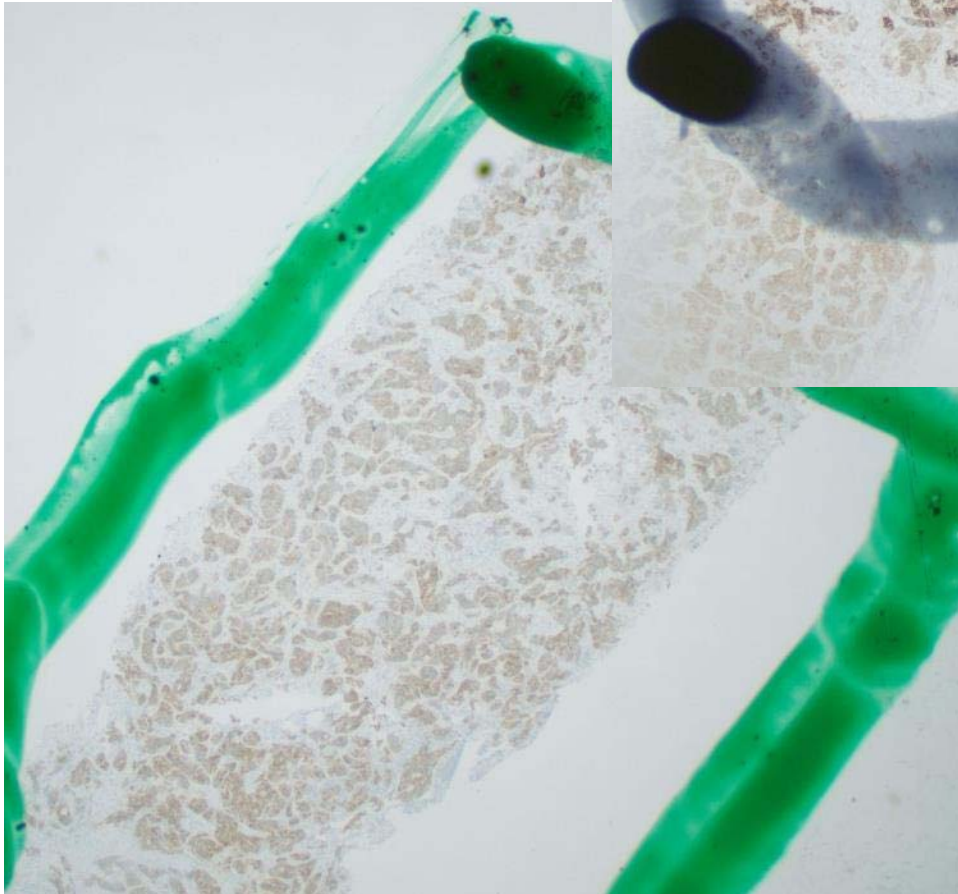


Your
Interpretation:

- A. 0
- B. 1+
- C. 2+
- D. 3+
- E. Other



FISH Testing of Heterogeneous Cases



Pathologist needs to direct
exactly where to FISH!!
Circle areas of separate intensity
levels by IHC and ask for
separate counts in the two areas

2013 Guidelines: HER2 Heterogeneity by FISH

- Must score separately an aggregated positive population that is > 10% of total tumor population
- Report must include:
 - HER2 status as positive with the percentage of the total tumor that is amplified
 - Ratio and signals/cell of both populations

See Table 1 “ISH Interpretation” and Data Supplement 8:

ISH Interpretation Criteria *ASCO/CAP HER2 Testing Guideline Update*—Wolff et al

2013 Guidelines: ISH Interpretation

- Pathologist should either scan ISH slide prior to counting OR use IHC to define the areas of potential HER2 amplification
 - Implies Dual Testing by IHC and FISH if the pathologist cannot be at the fluorescence scope
 - Reason: To rule out heterogeneity

See Table 1 “ISH Interpretation” and Data Supplement 8:

ISH Interpretation Criteria *ASCO/CAP HER2 Testing Guideline Update*—Wolff et al

Example report of heterogeneous case

FINAL DIAGNOSIS: Heterogeneous for HER2 gene amplification with the following features:

- a. Positive for HER2 gene amplification in 20% of the invasive carcinoma (ratio = 4.5, mean HER2 signals/cell = 8.5)
- b. Negative for HER2 gene amplification in 80% of the invasive carcinoma (ratio = 1.0, mean HER2 signals/cell = 2.0)

COMMENT:

This sample is heterogeneous for HER2 gene amplification. A distinct, clustered subpopulation, representing 20% of the invasive carcinoma is positive for HER2 gene amplification. The same area is also positive for HER2 over-expression. The remainder of the invasive cancer in this sample is HER2 negative. The 2013 CAP/ASCO HER2 testing guidelines would consider this a HER2 positive result and the patient should be considered a candidate for HER2 targeted therapy.

Unusual HER2 IHC staining:

Strong cytoplasmic staining only



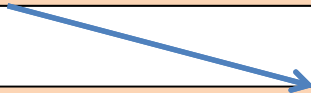
Recommend calling Equivocal (2+) and sending to ISH testing

Heterogeneous staining (distinct separate areas with different staining patterns)



Recommend evaluating as separate areas if going to perform ISH. An amplified result in >10% in a clustered pattern is considered a positive result (document percent positive and note heterogeneity).

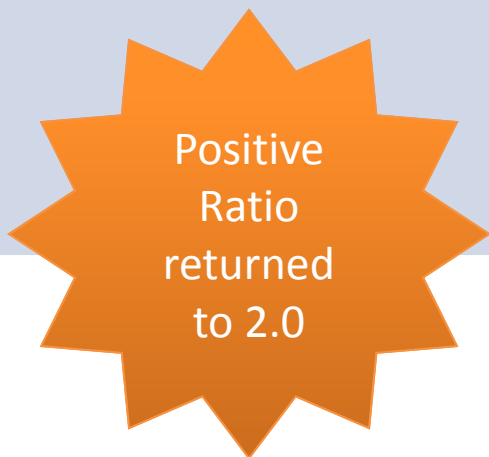Discordant result with histology (grade 1 or pure tubular or mucinous carcinoma that is HER2 3+)



Recommend re-evaluating grade/histologic subtype as well as HER2 test. Additional testing on subsequent specimens may be required to resolve.

2013 Guidelines: What is a HER2 FISH/ISH positive result?

2007 Recommendations	2013 Recommendations
<p>Positive: FISH ratio > 2.2 or > 6 average HER2 signals/cell</p>	<p>Positive: Single probe ISH with average HER2 copy number ≥ 6.0 or Dual probe ISH with ratio $\geq 2.0^*$; with an average HER2 copy number ≥ 4 signal/cell or Dual probe ISH with ratio $\geq 2.0^*$; with an average HER2 copy number < 4 signal/cell[^] or Dual probe ISH with ratio $< 2.0^*$; with an average HER2 copy number ≥ 6.0 signals/cell[*]</p>



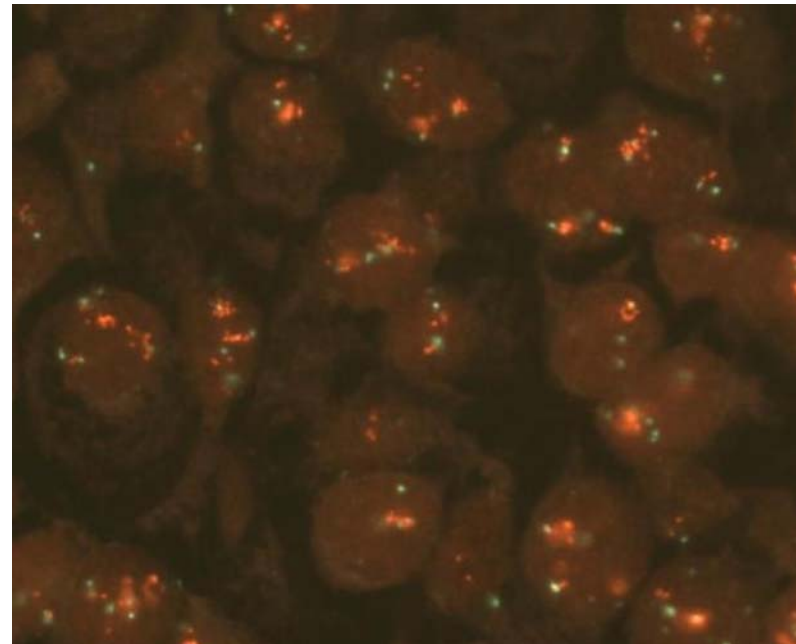
*observed in a homogeneous and contiguous population and within $>10\%$ of the invasive tumor cells

[^]See Data Supplement 2e for additional information

ASCO/CAP HER2 Testing Guideline Update—Wolff et al

HER2 FISH

- Positive for HER2 gene amplification



Cell	HER2	CEP17
1	15	2
2	9	2
3	7	1
4	12	2
5	10	2
6	10	1
7	8	3
8	2	2
9	2	2
10	8	2
11	15	1
12	12	3
13	8	2
14	2	2
15	7	2
16	9	2
17	12	1
18	12	2
19	15	2
20	10	3
Mean	9.25	1.95
Ratio	4.74	



Must include both mean signals/cell
and ratio on report!

Co-amplification / "Polysomy"

Cell	HER2	CEP17
Mean	7.85	6.9
Ratio	1.14	

- Data Supplement 2B and 2E:
 - True polysomy is rare (more common = co-amplification of peri-centromeric regions)
 - May result in protein over-expression
 - Evidence is mixed on if cancers with this profile respond to HER2 targeted therapy
 - Considered a positive result (treatable)

Example report: Coordinate Amplification

FINAL DIAGNOSIS:

Positive for HER2 gene amplification with coordinately increased HER2 and CEP17 signals (ratio = 1.14, mean HER2 signals/cell = 7.85, mean CEP17 = 6.9); See comment

COMMENT:

This cancer has ≥ 6.0 mean HER2 signals/cell but coordinately increased centromeric control signals resulting in a HER2:CEP17 ratio < 2.0 . Because array-based comparative genomic hybridization (aCGH) studies have shown that true polysomy (duplication of the entire chromosome) is actually rare, while gain of the pericentromeric region of chromosome 17 is more commonly observed, the 2013 CAP/ASCO HER2 Testing Guidelines Update recommends considering these cases positive. However, there is limited data to indicate if patients receive benefit from HER2 targeted therapy in this setting without over-expression of the HER2 protein by IHC. This sample was 2+ by IHC.

Monosomy example

	HER2	CEP17
Mean	3.4	1.2
Ratio	2.8	

FINAL DIAGNOSIS:

Positive for HER2 gene amplification by ratio with loss of CEP17 signal (ratio = 2.8, mean HER2 signals/cell = 3.4, mean CEP17 = 1.2); See comment

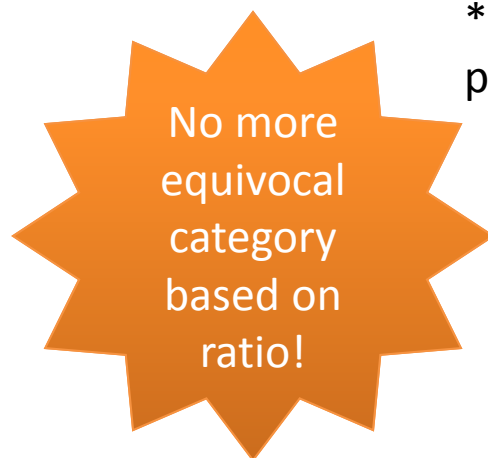COMMENT:

This cancer has an average CEP17 signal of <2.0 resulting in a HER2/CEP17 ratio ≥ 2.0 by ISH, despite a low average HER2 copy number < 4.0. There is limited data on how these patients respond to HER2 targeted therapy. However, the 2013 CAP/ASCO HER2 Testing Guidelines Update recommended considering these cases HER2 positive based on limited data on a similar group of patients included in the HERA trials that did not show reduced benefit for trastuzumab. However, the guidelines panel also recommended consideration of further HER2 testing in this setting. This case was HER2 ___ by IHC.

2013 Guidelines: What is FISH/ISH Equivocal?

2007 Recommendations	2013 Recommendations
ISH Equivocal: FISH ratio 1.8-2.2 or 4-6 average HER2 signals/cell	ISH Equivocal: Single probe ISH with average HER2 copy number ≥ 4.0 and < 6.0 signals/cell* Or Dual probe ISH with ratio < 2.0 ; with an average HER2 copy number ≥ 4.0 and < 6.0 signals/cell*

*observed in a homogeneous and contiguous population and within $>10\%$ of the invasive tumor cells



Per Data Supplement 8: ISH Interpretation Criteria
If *HER2/CEP17* ratio between 1.8 and 2.2, have an additional person count an additional 20 non-overlapping cells

Example report: Equivocal FISH

	HER2	CEP17
Mean	4.85	2.7
Ratio	1.79	

FINAL DIAGNOSIS:

Equivocal for HER2 gene amplification (ratio = 1.79, mean HER2 signals/cell = 4.85, mean CEP17 = 2.7); See comment

COMMENT:

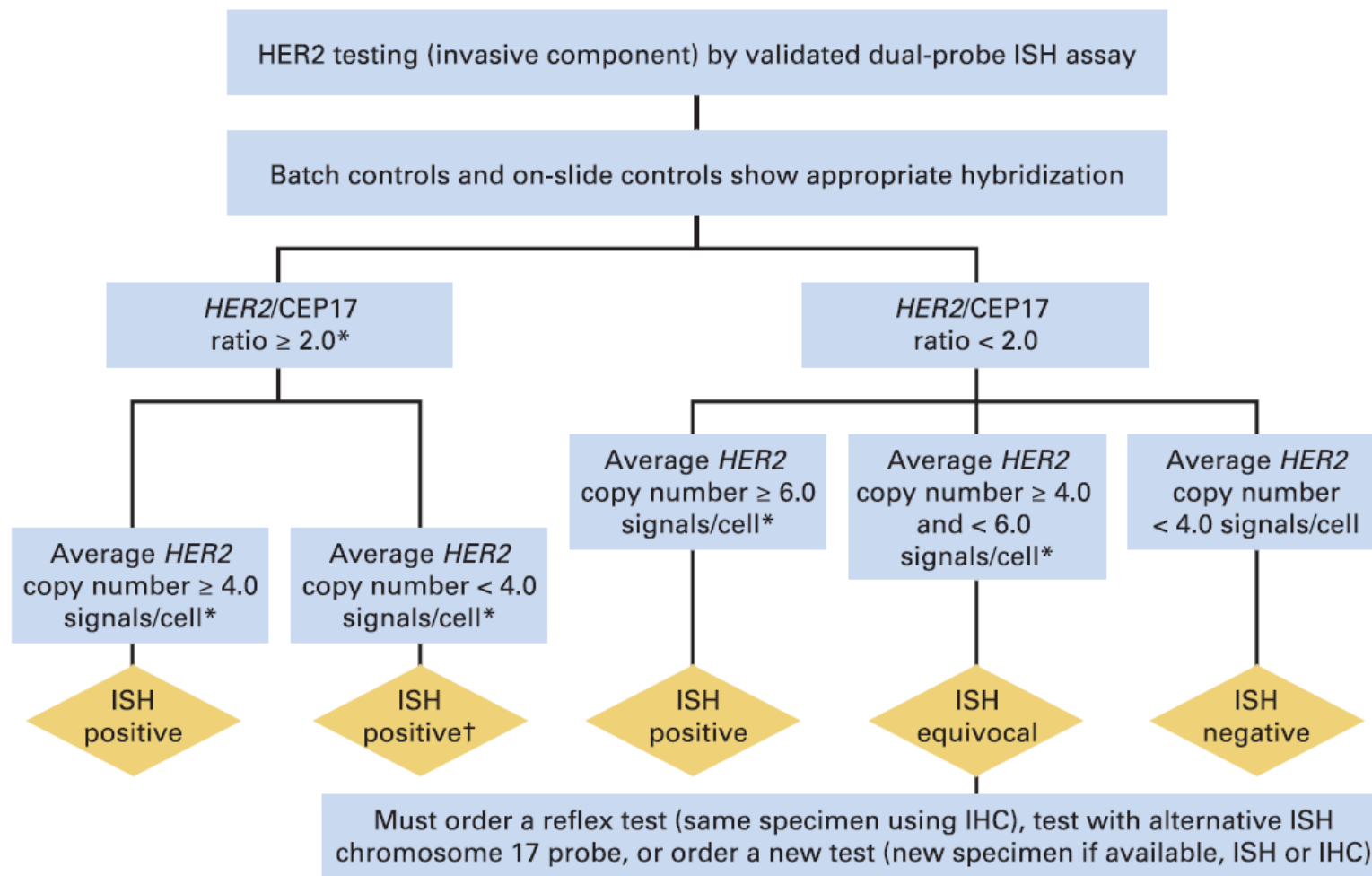
This cancer has a negative ratio (< 2.0) and an equivocal mean HER2 signals/cell between (≥ 4 and < 6). The case was notable for scattered, intermixed cells with increased HER2 signal, the significance of which is unclear. The 2013 CAP/ASCO HER2 Testing Guidelines Update recommends reporting cases with these results as equivocal for HER2 gene amplification. There is limited data to indicate if patients receive benefit from HER2 targeted therapy in this setting without over-expression of the HER2 protein by IHC. This sample was ___ by IHC. Additional HER2 testing is recommended on additional samples if/when available.

2013 Guidelines: What is FISH/ISH Negative?

2007 Recommendations	2013 Recommendations
ISH Negative: FISH ratio < 1.8 or < 4 average HER2 signals/cell	ISH Negative: Single probe ISH with average HER2 copy number < 4.0 signals/cell or Dual probe ISH with ratio < 2.0; with an average HER2 copy number < 4.0 signals/cell*

*observed in a homogeneous and contiguous population and within >10% of the invasive tumor cells

ISH Summary

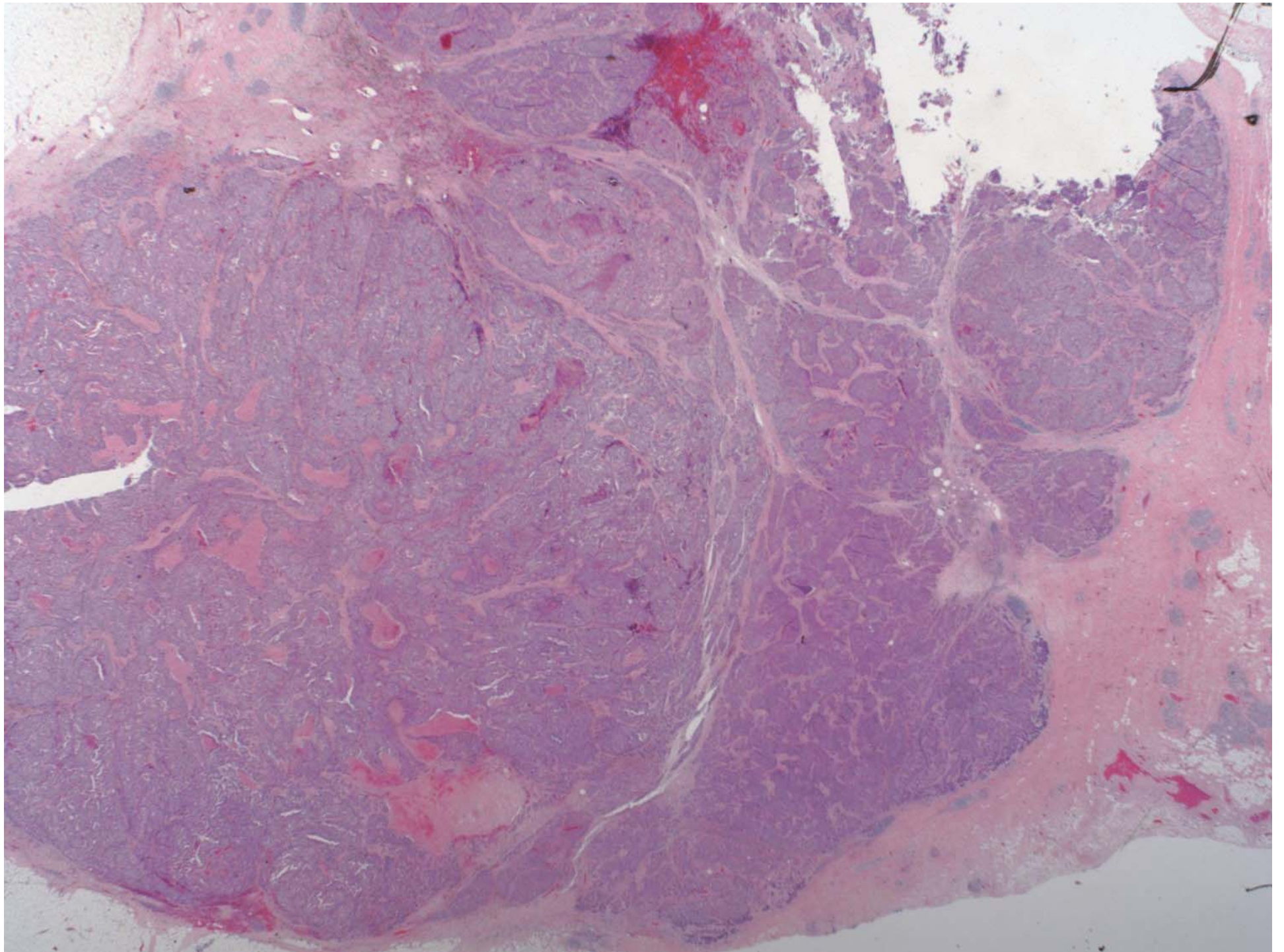


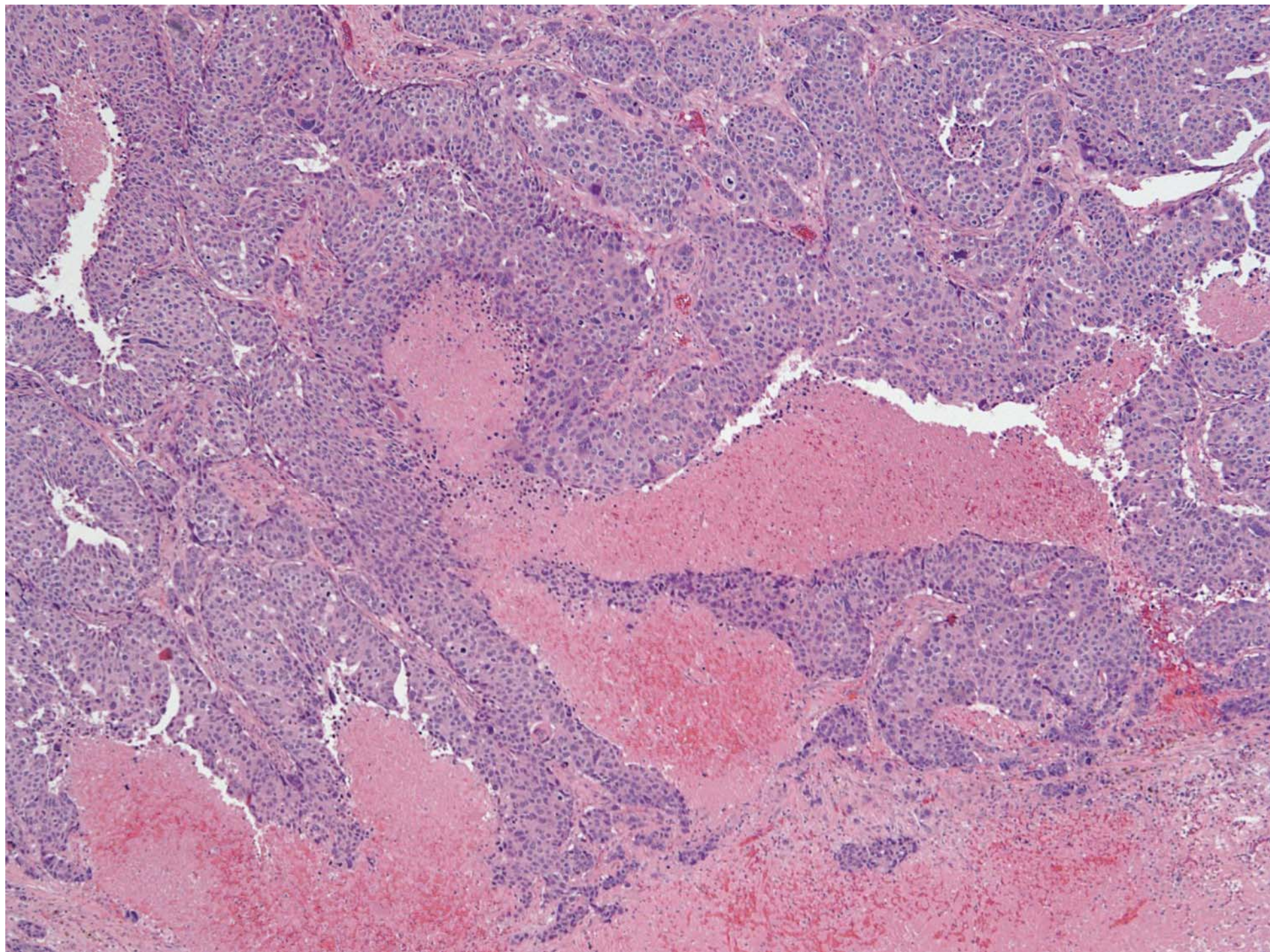
Take-Home Points for HER2 Testing

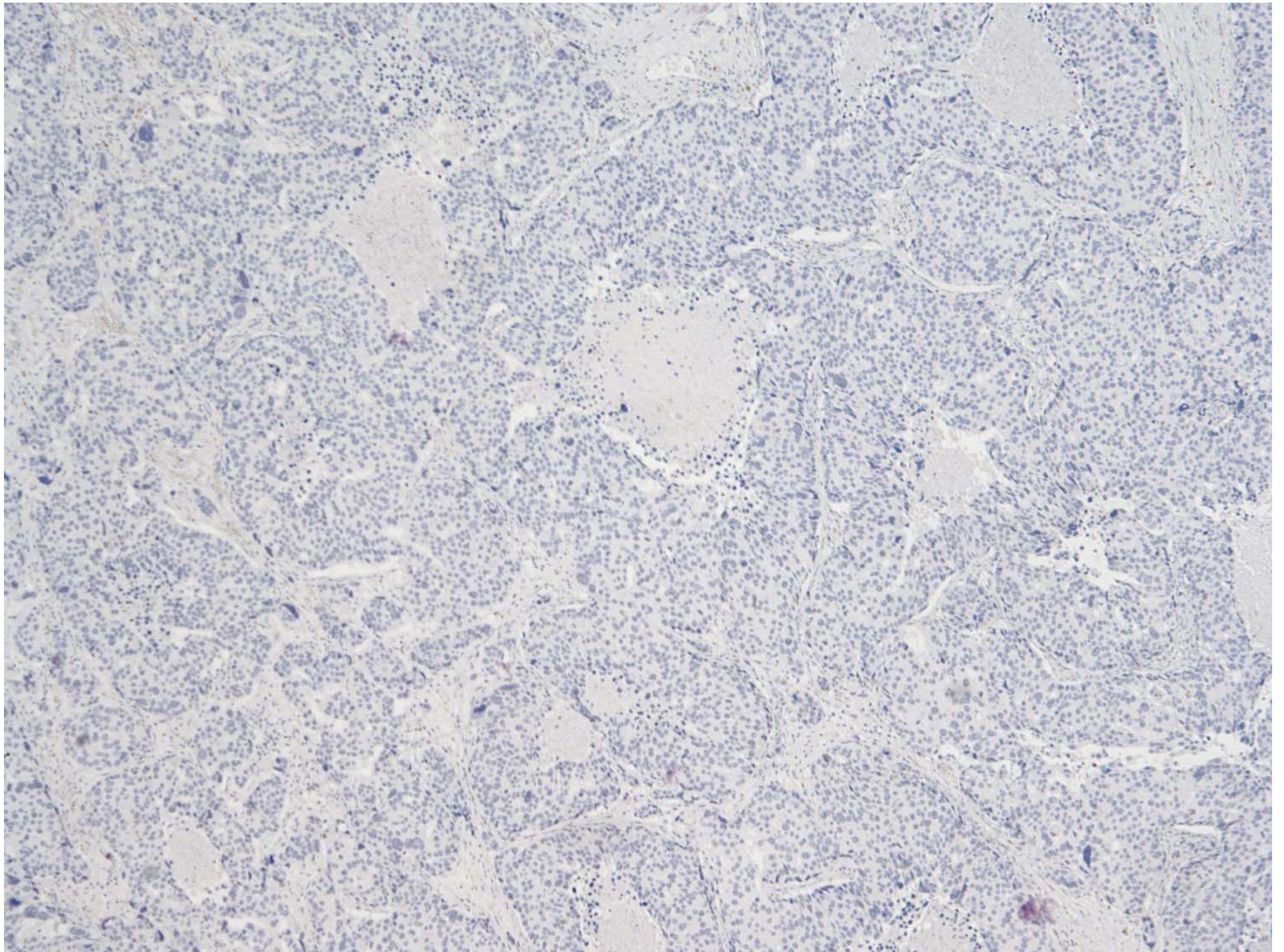
- Know new thresholds for HER2 positive, equivocal, negative by IHC and ISH
 - IHC: 30%→10% change for 3+
 - FISH: Return to 2.0 ratio but use HER2 signals/cell as well
 - Still recount cases close to positive threshold
- Have strict criteria for a HER2 3+ result by IHC
 - Keep your threshold for strong intensity of staining high!
- Correlate HER2 status with histology/biology
 - Work-up discordant cases!
- Screen for heterogeneity by IHC or FISH
 - Direct where to FISH appropriately!

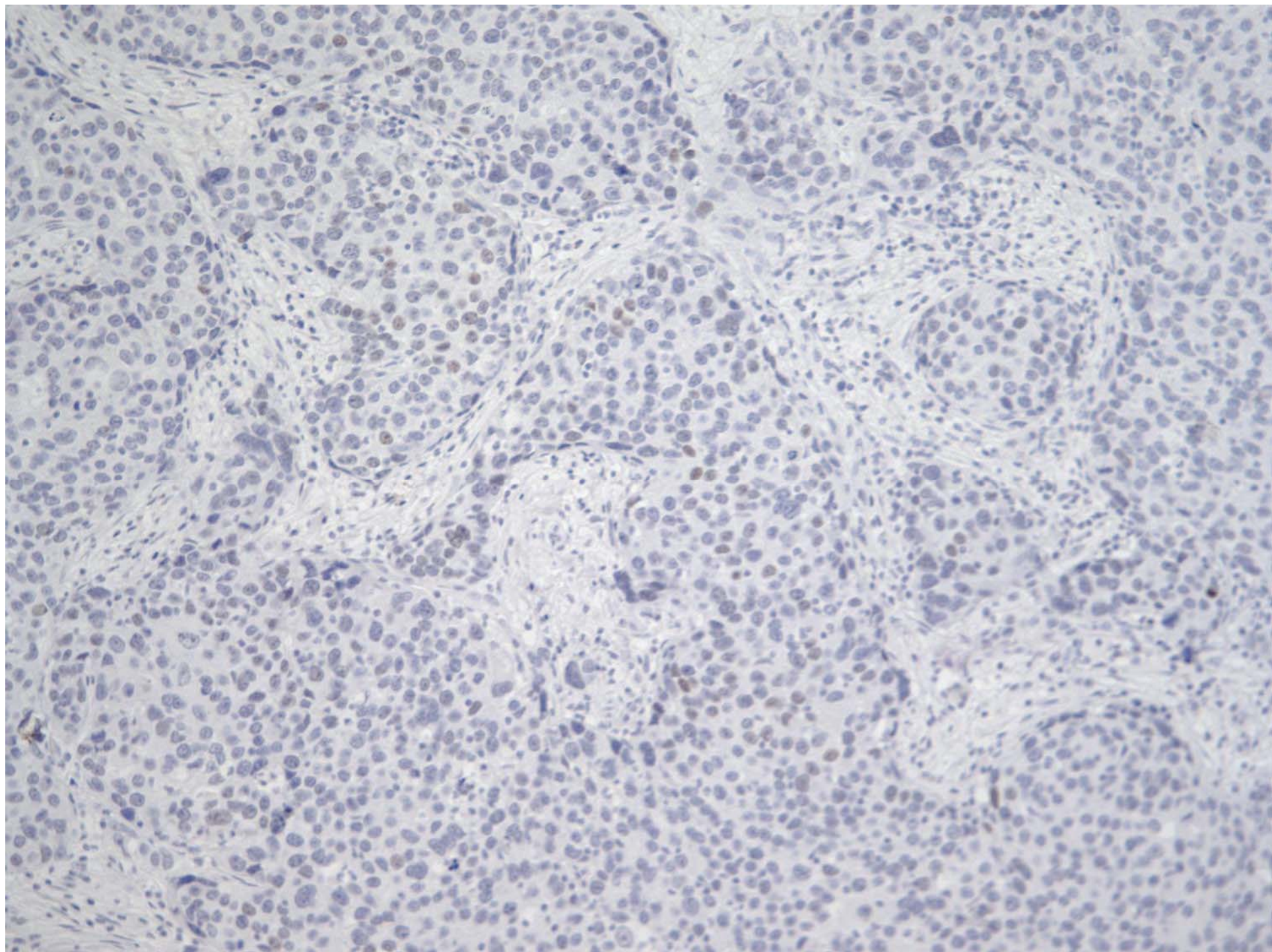
Test Case 4

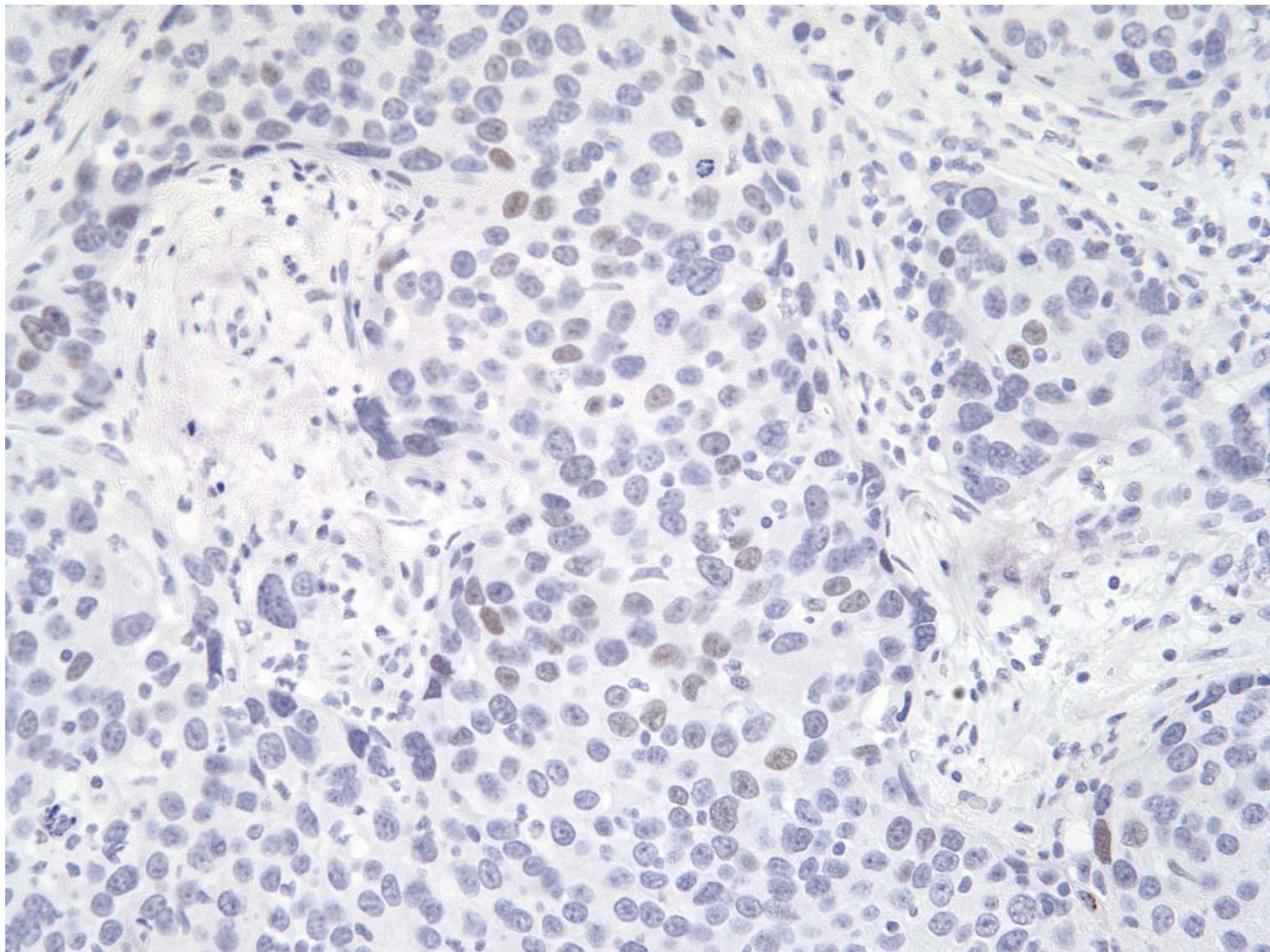
37 year old with invasive breast
cancer

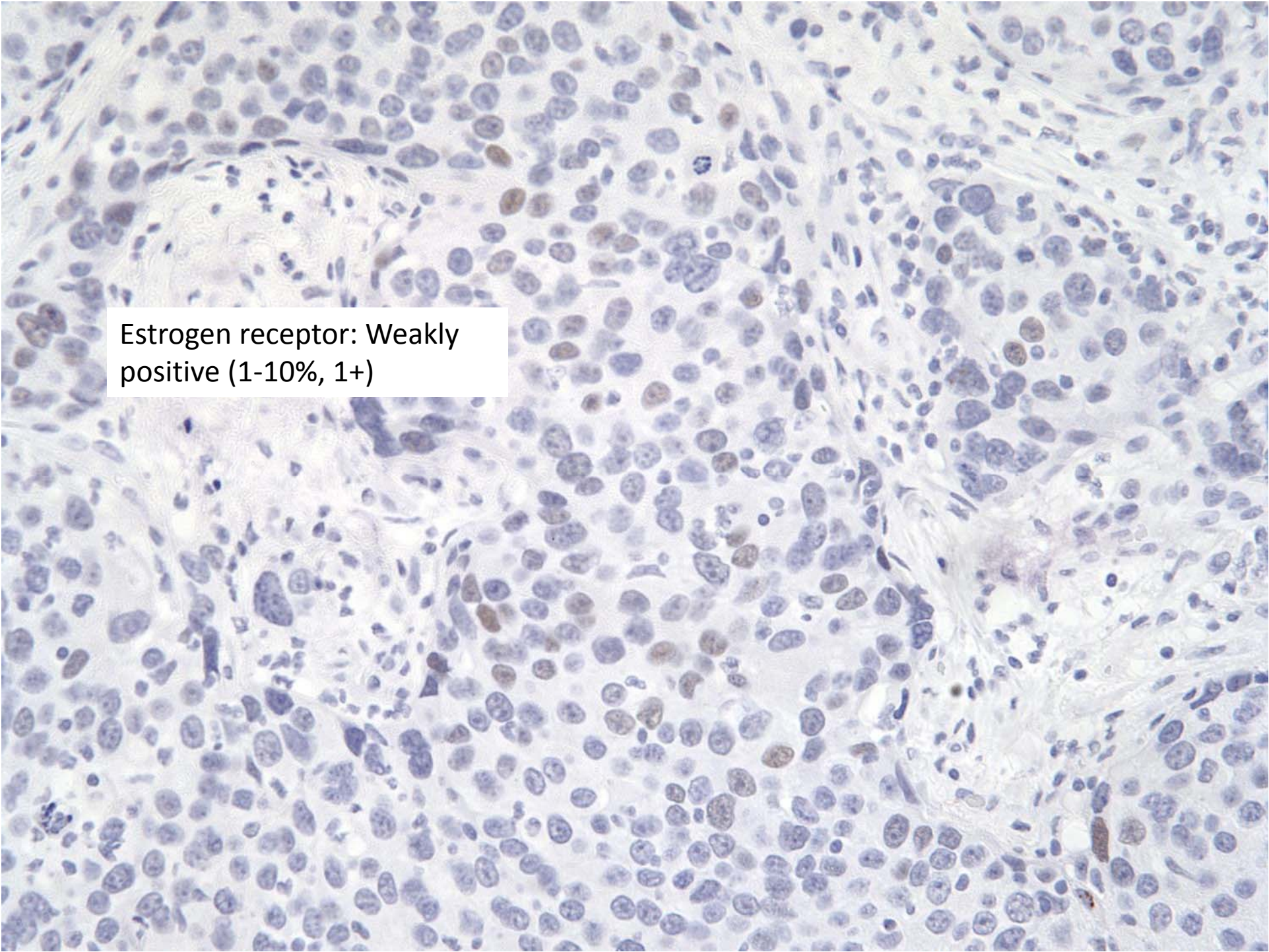






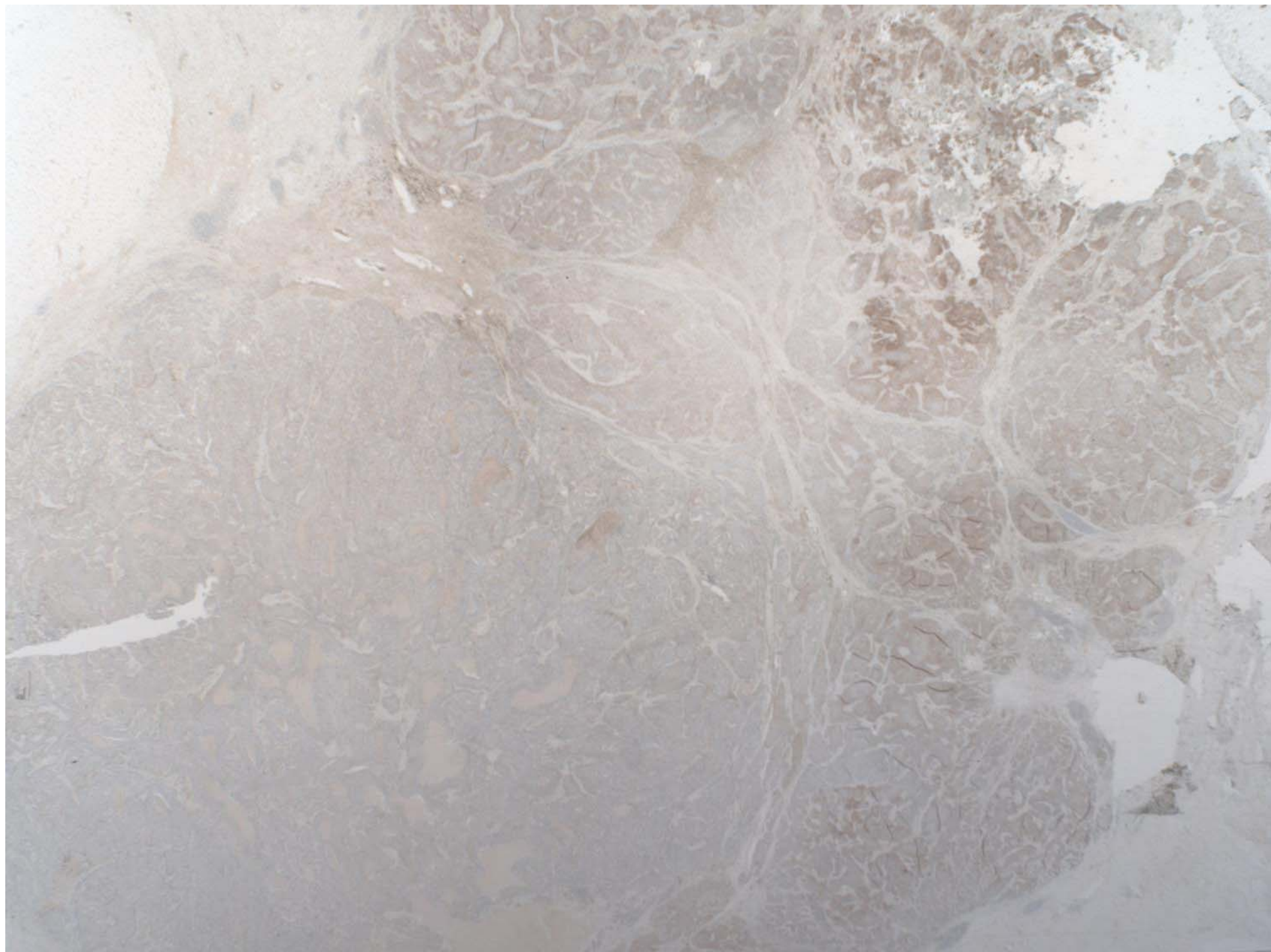


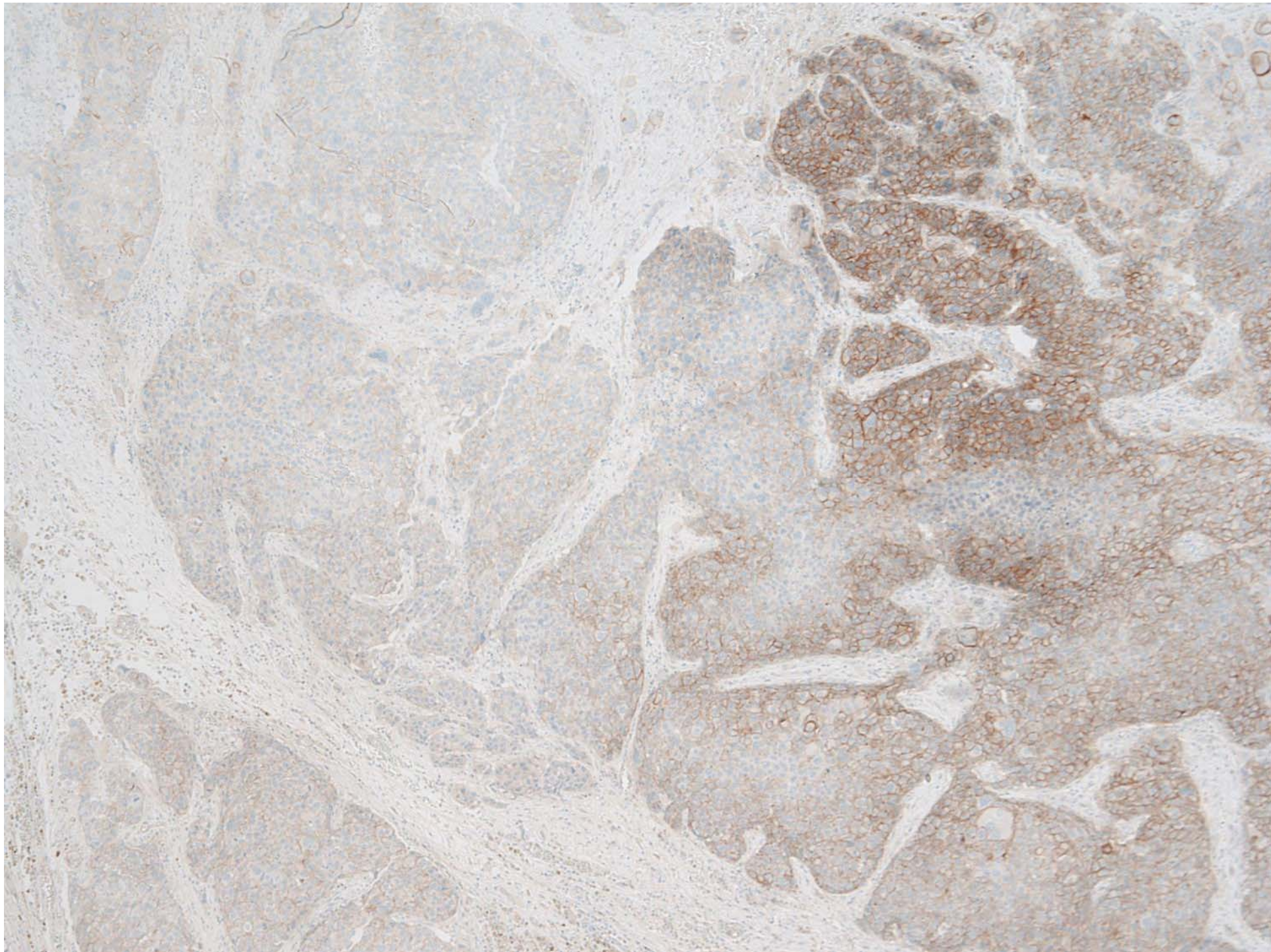


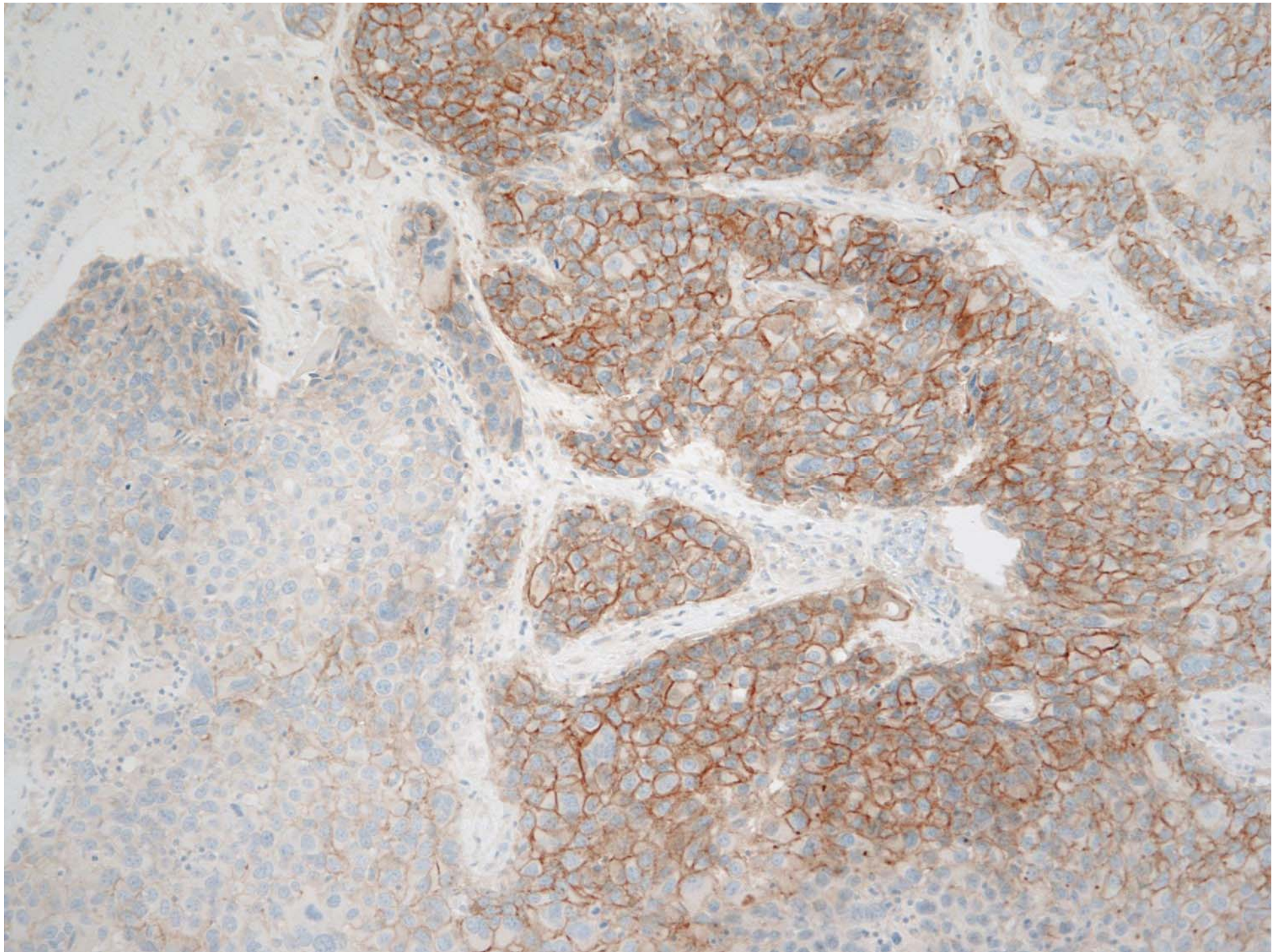


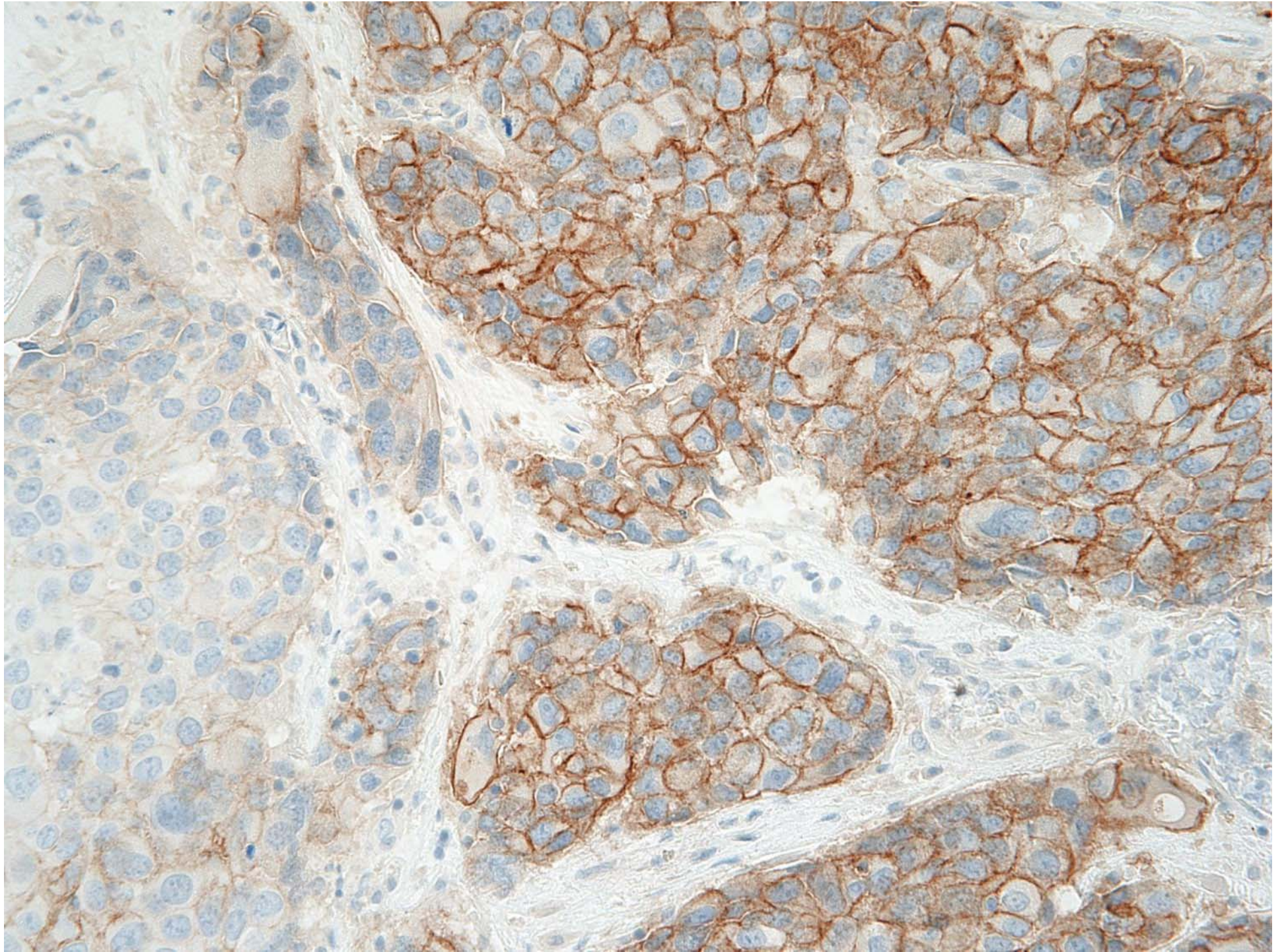
Estrogen receptor: Weakly
positive (1-10%, 1+)

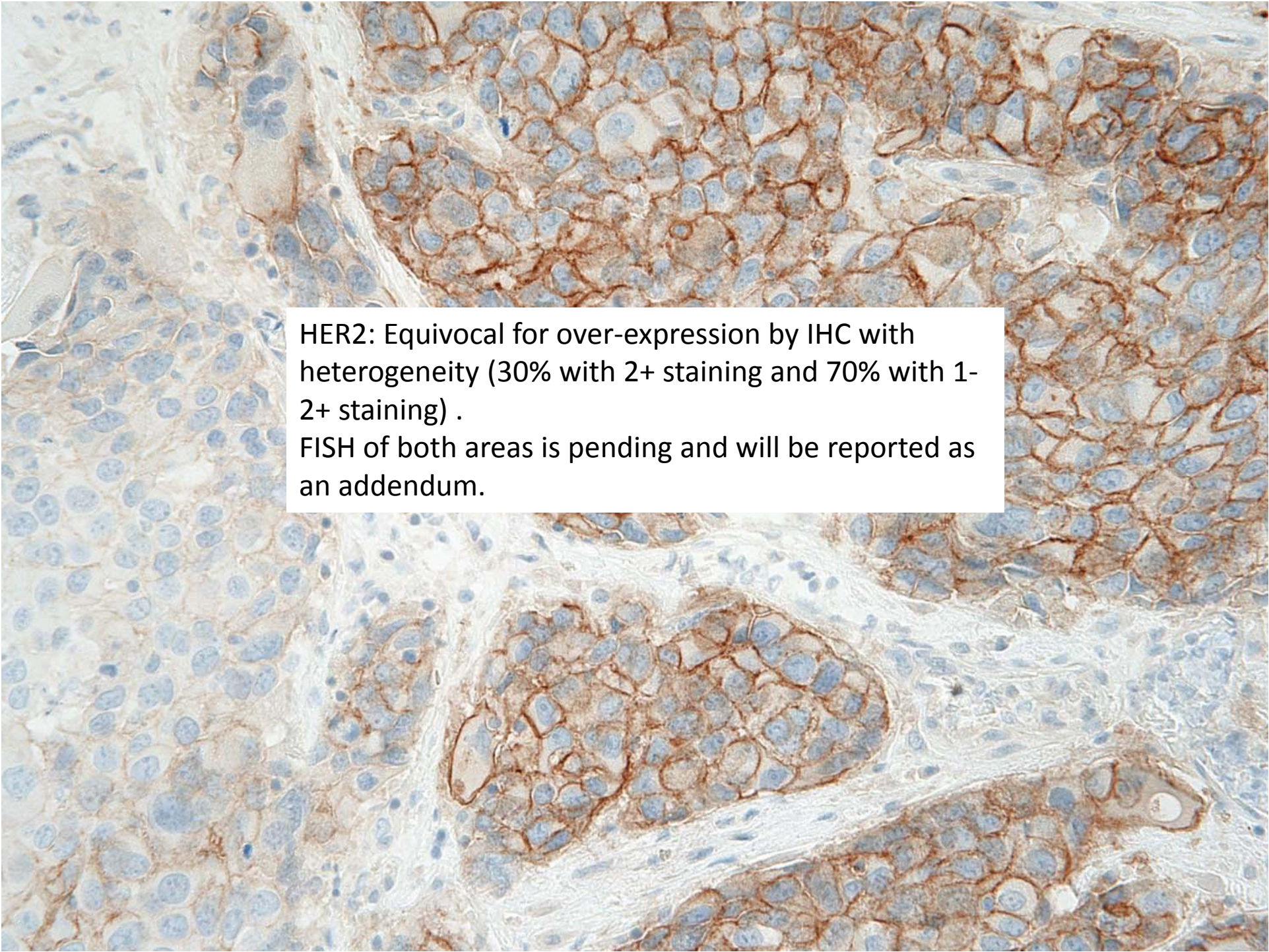
This histological slide shows a dense population of cells with prominent, dark blue nuclei. The cells are arranged in a somewhat disorganized pattern, typical of a tumor. The background is a light, pinkish-purple color, indicating the presence of connective tissue and other cellular components. The overall appearance is consistent with a breast tissue sample undergoing immunohistochemical analysis for estrogen receptor status.











HER2: Equivocal for over-expression by IHC with heterogeneity (30% with 2+ staining and 70% with 1-2+ staining) .
FISH of both areas is pending and will be reported as an addendum.



FISH:

Ratio HER2:CEP17 = 1.07

Mean H2N/cell = 2.36

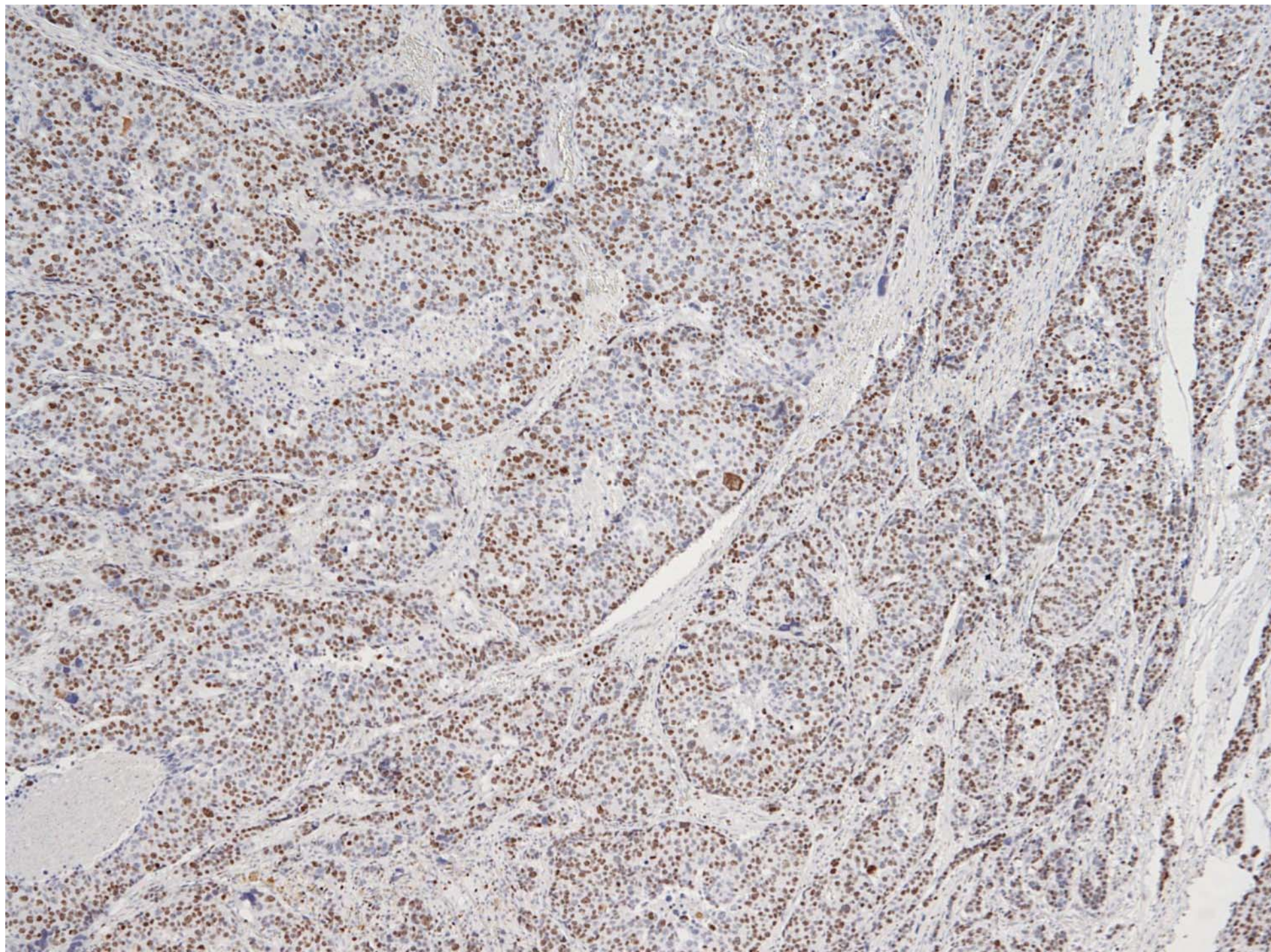
Mean CEP17/cell= 2.2

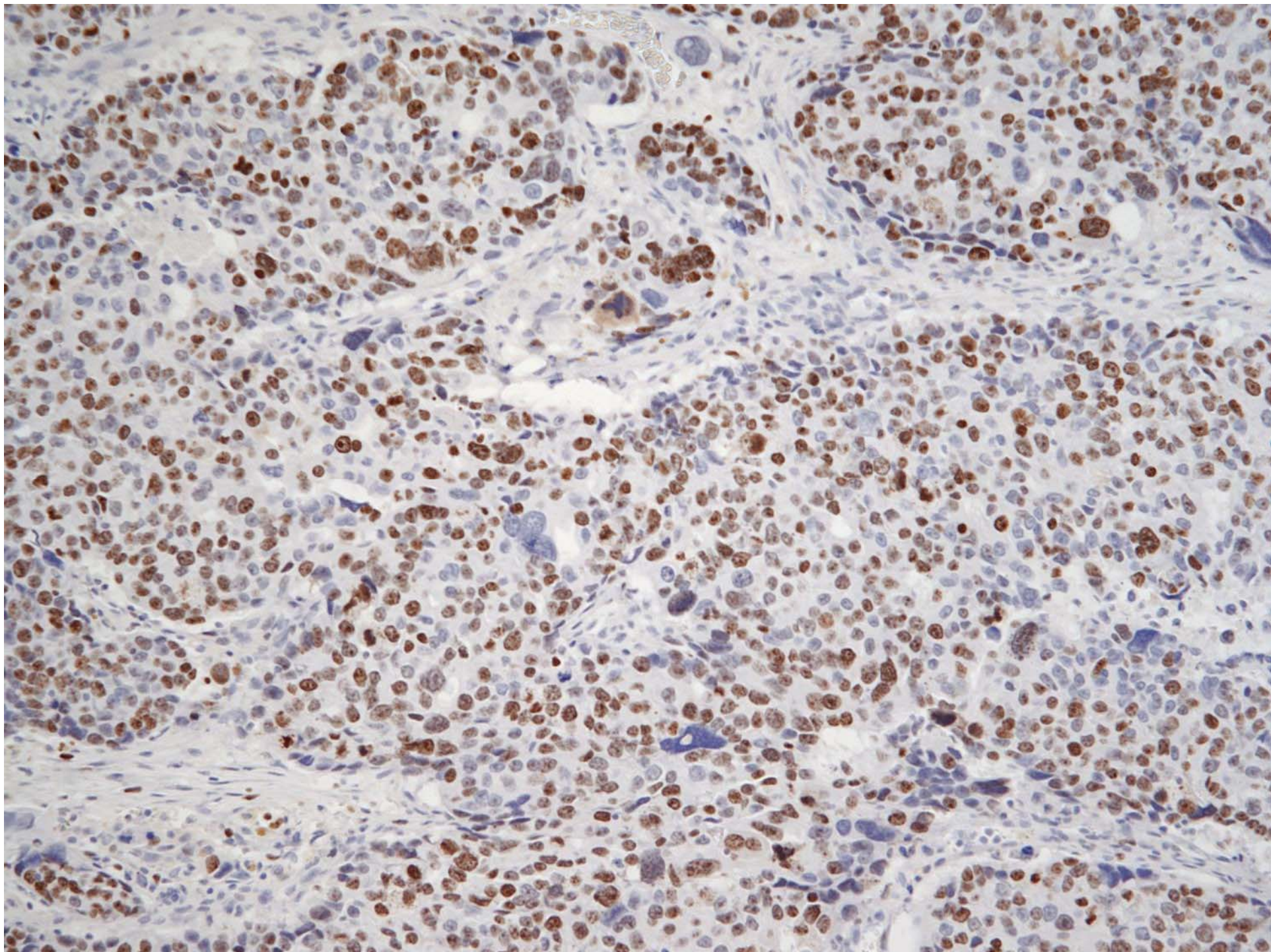
FISH:

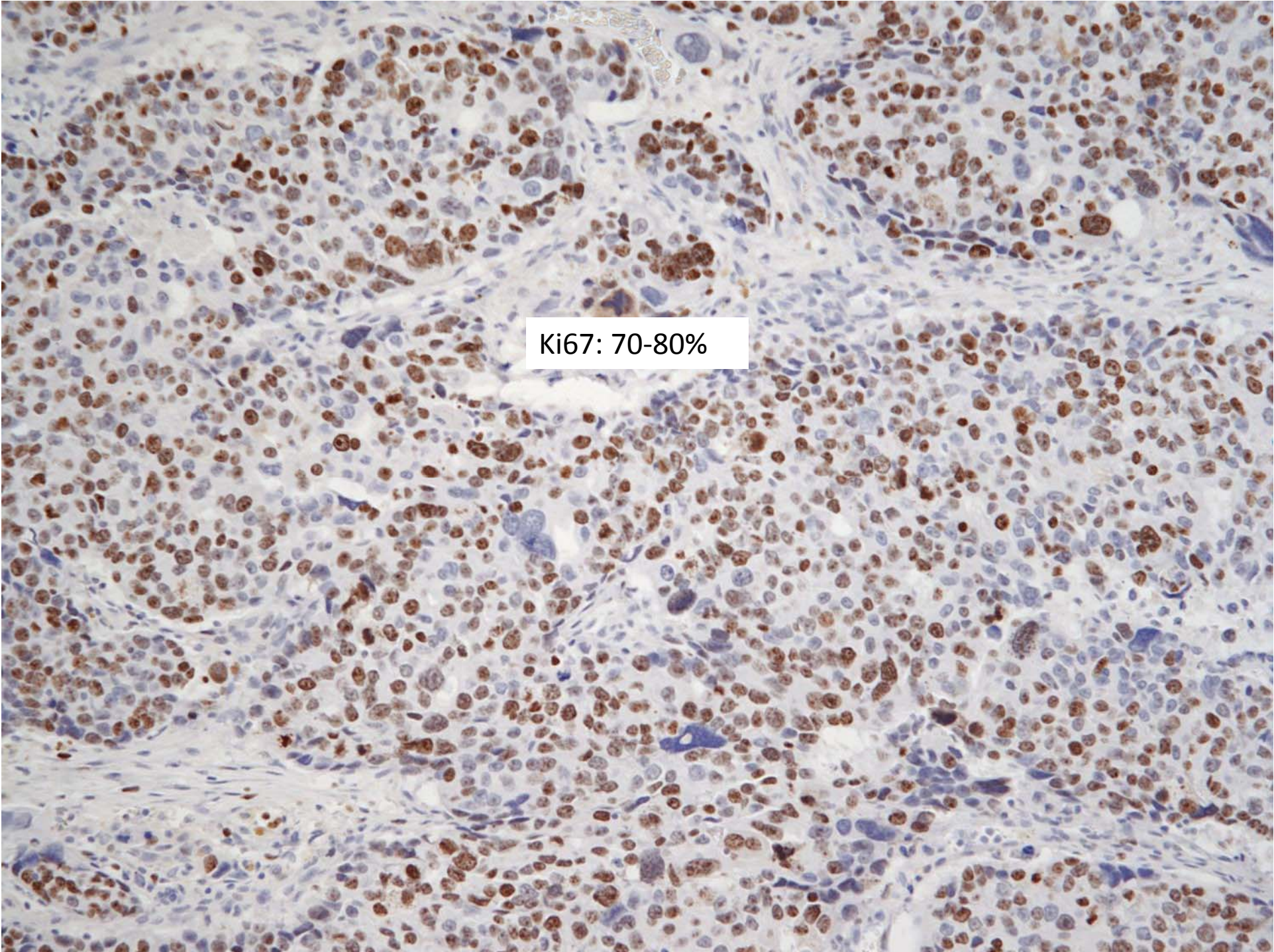
Ratio HER2:CEP17 = 0.57

Mean H2N/cell = 1.88

Mean CEP17/cell= 3.08







This histological slide displays a dense population of cells with prominent brown nuclear staining, indicating a high proliferation index. The cells are arranged in a disorganized pattern, typical of malignant tissue. The brown staining is widespread across the field of view, with very few cells showing only blue counterstain. A white text box is overlaid on the center of the image.

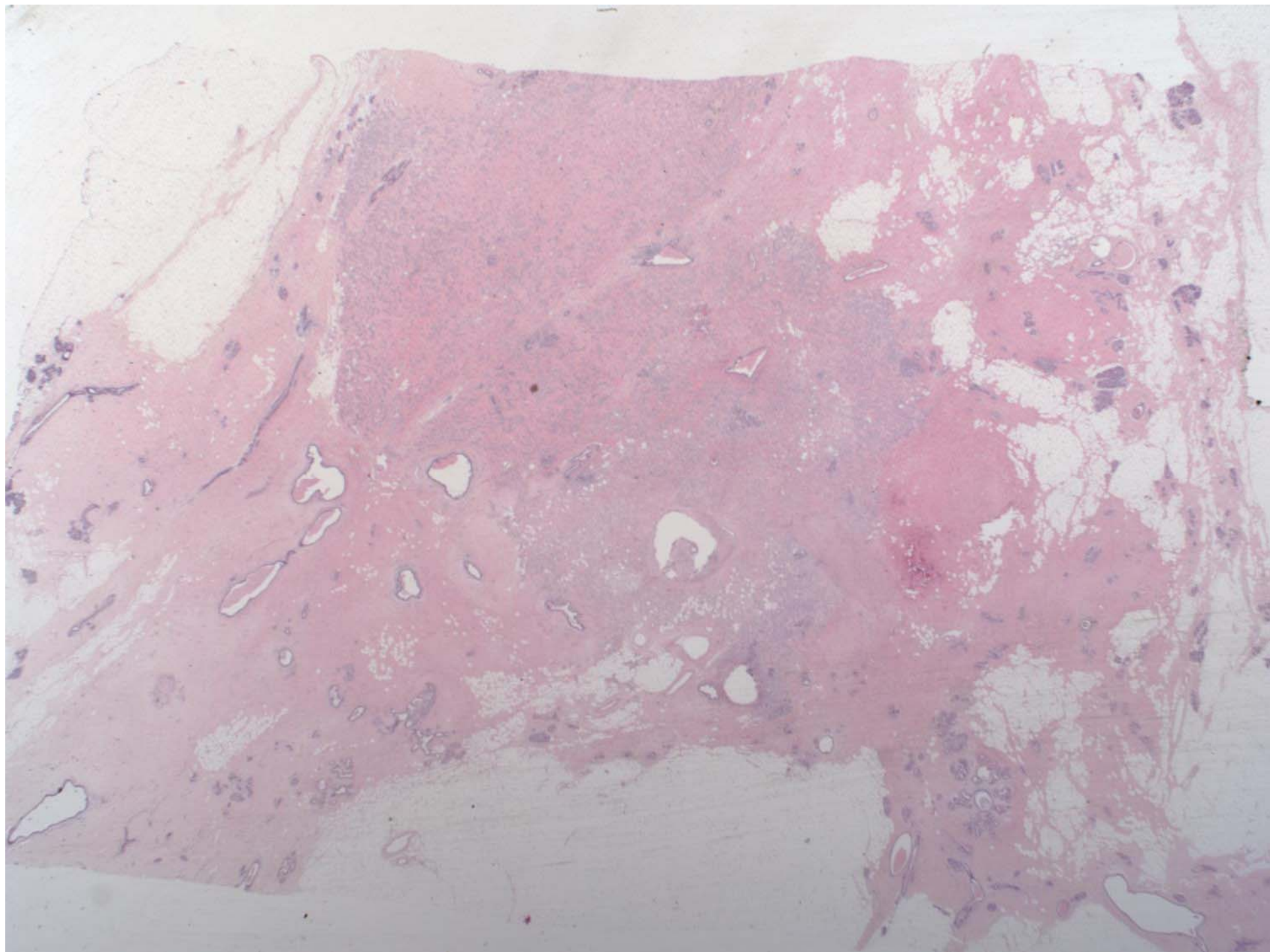
Ki67: 70-80%

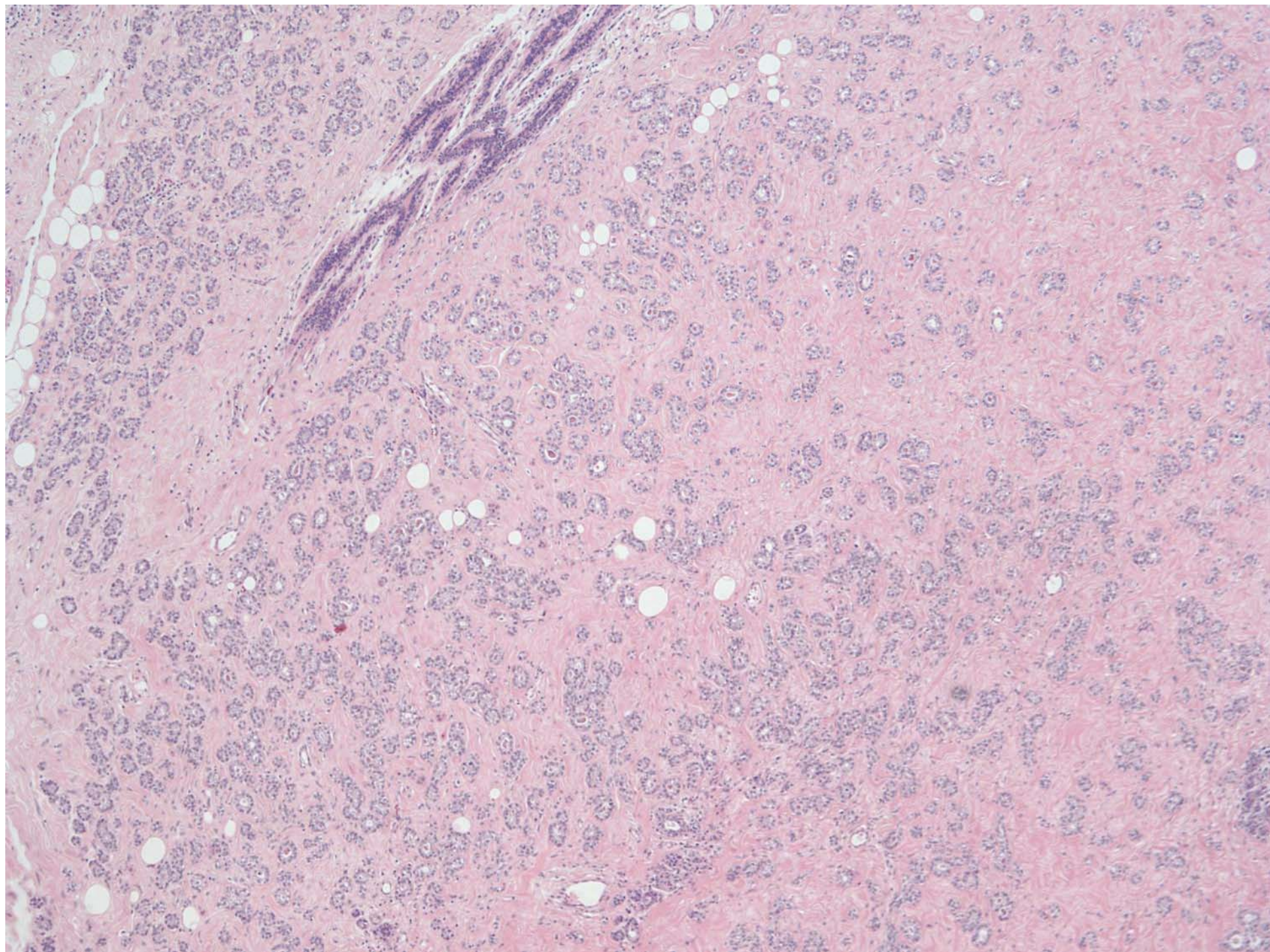
Take home points Case 4:

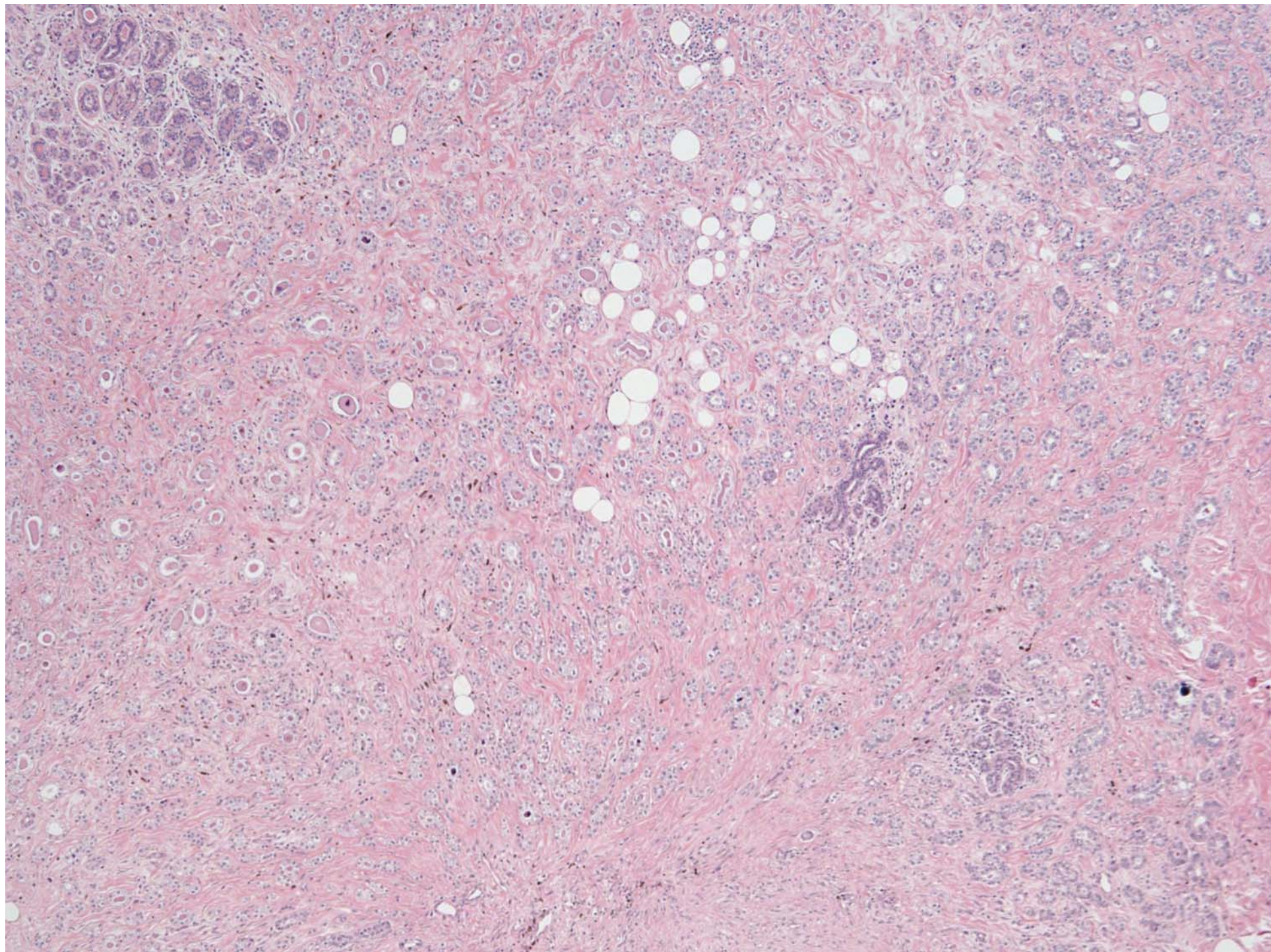
- Weak ER staining counts! CAP/ASCO threshold for positive is 1% weak staining
- Note HER2 heterogeneity on IHC and FISH different areas of expression separately
- Ki67 high in this case (more critical range is 10-15%)
- Mention basal-like features on histology in this case

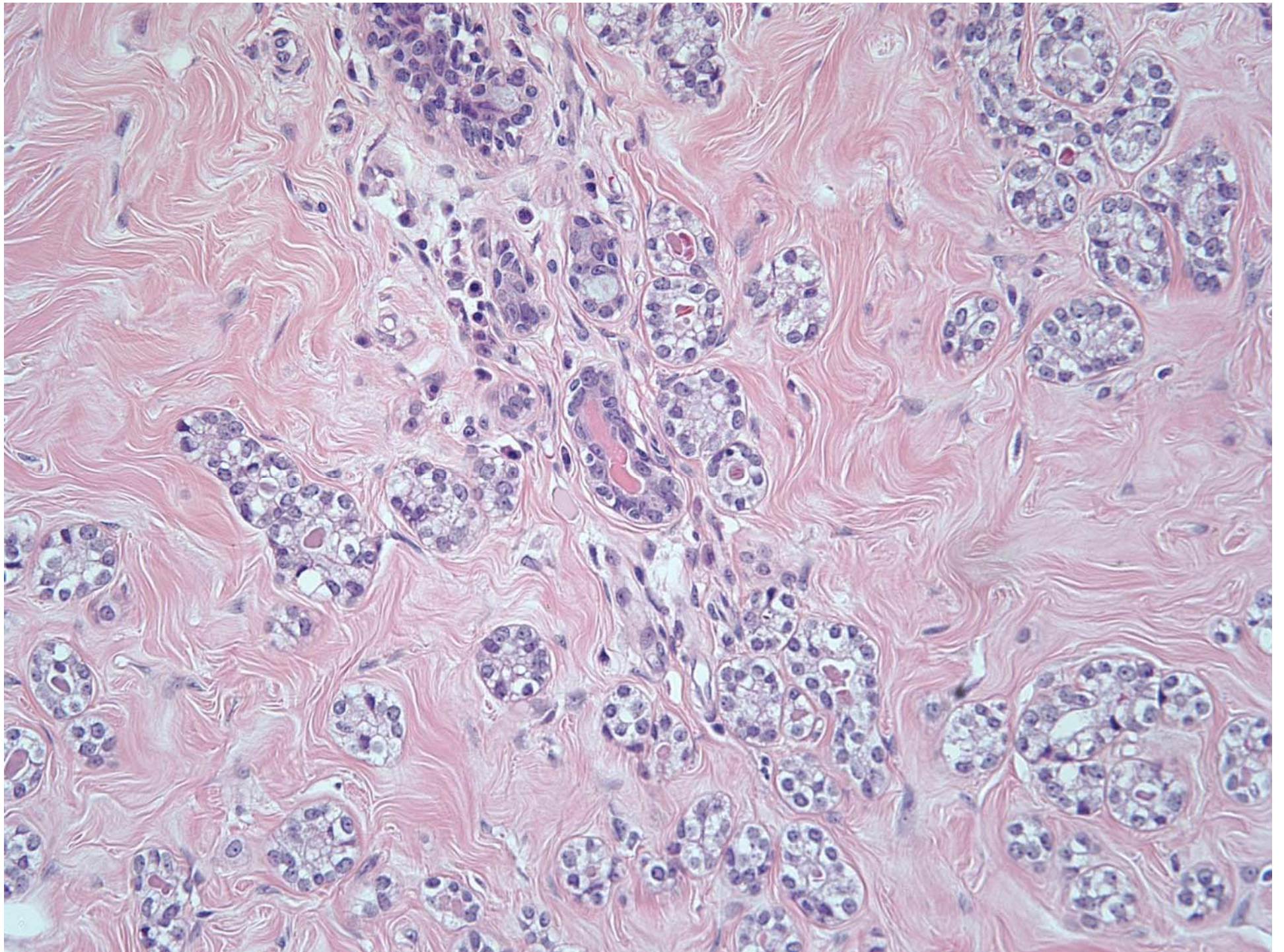
Case 5

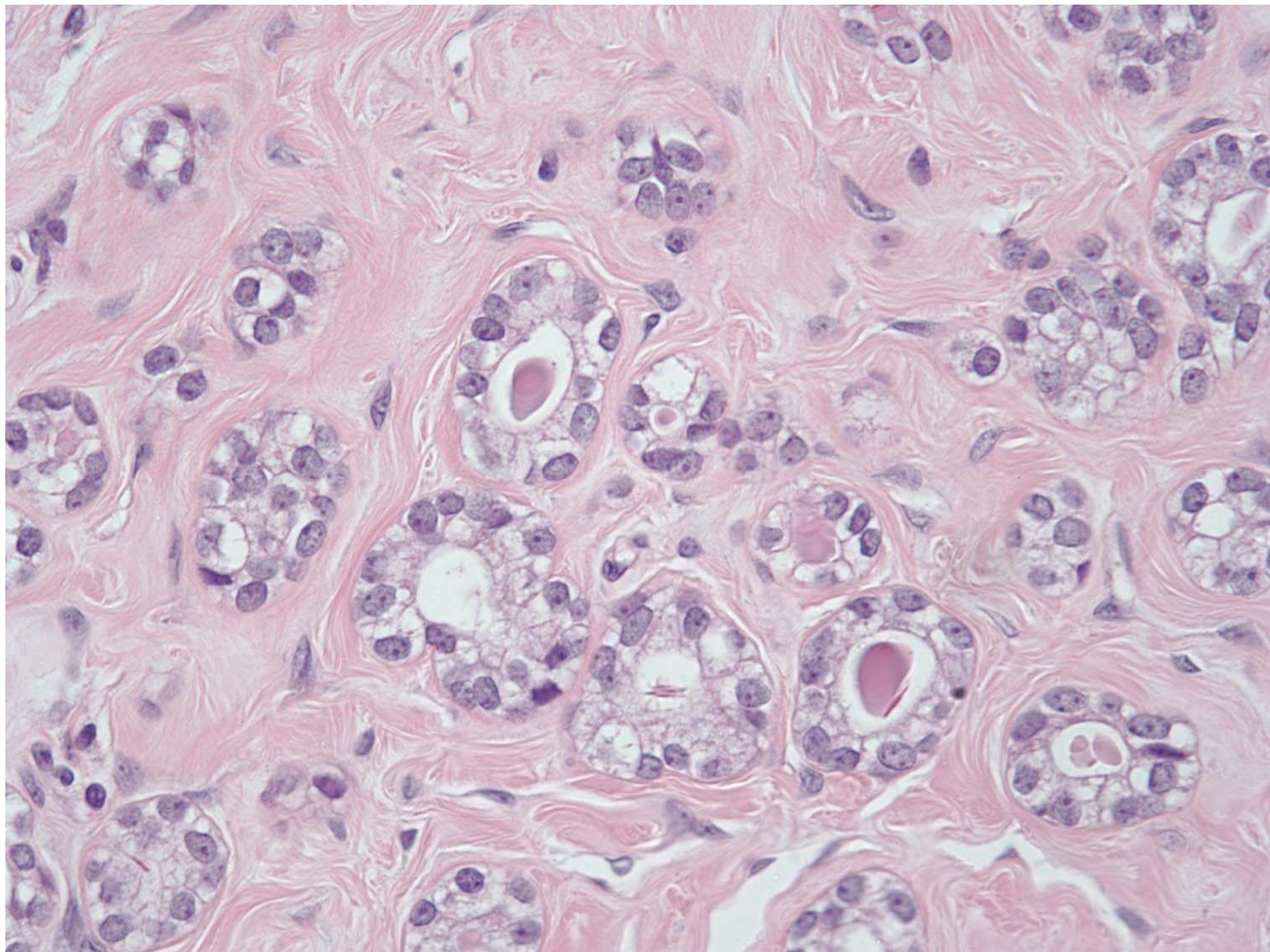
59 year old with excision for IDC on
core



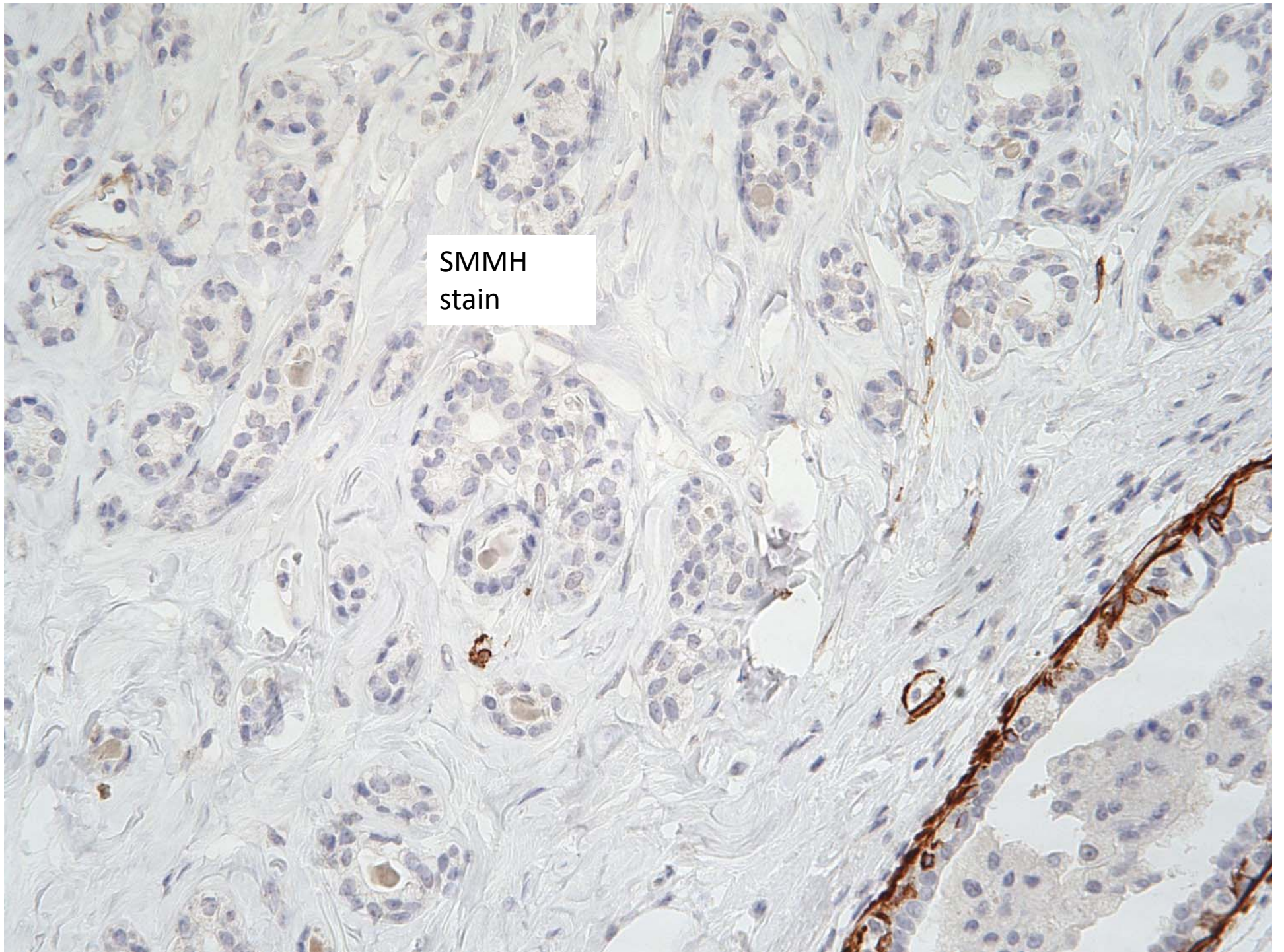


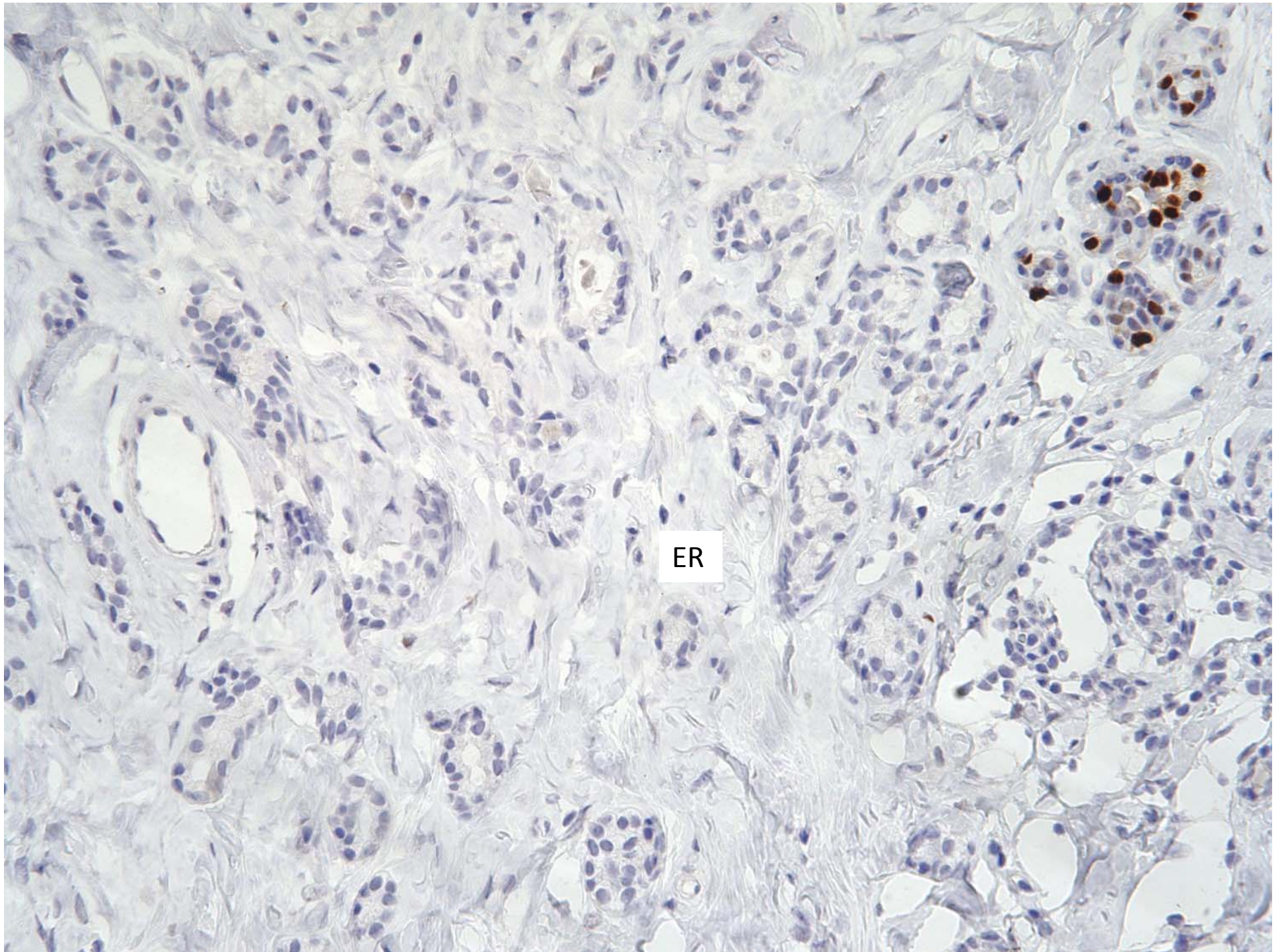






SMMH
stain



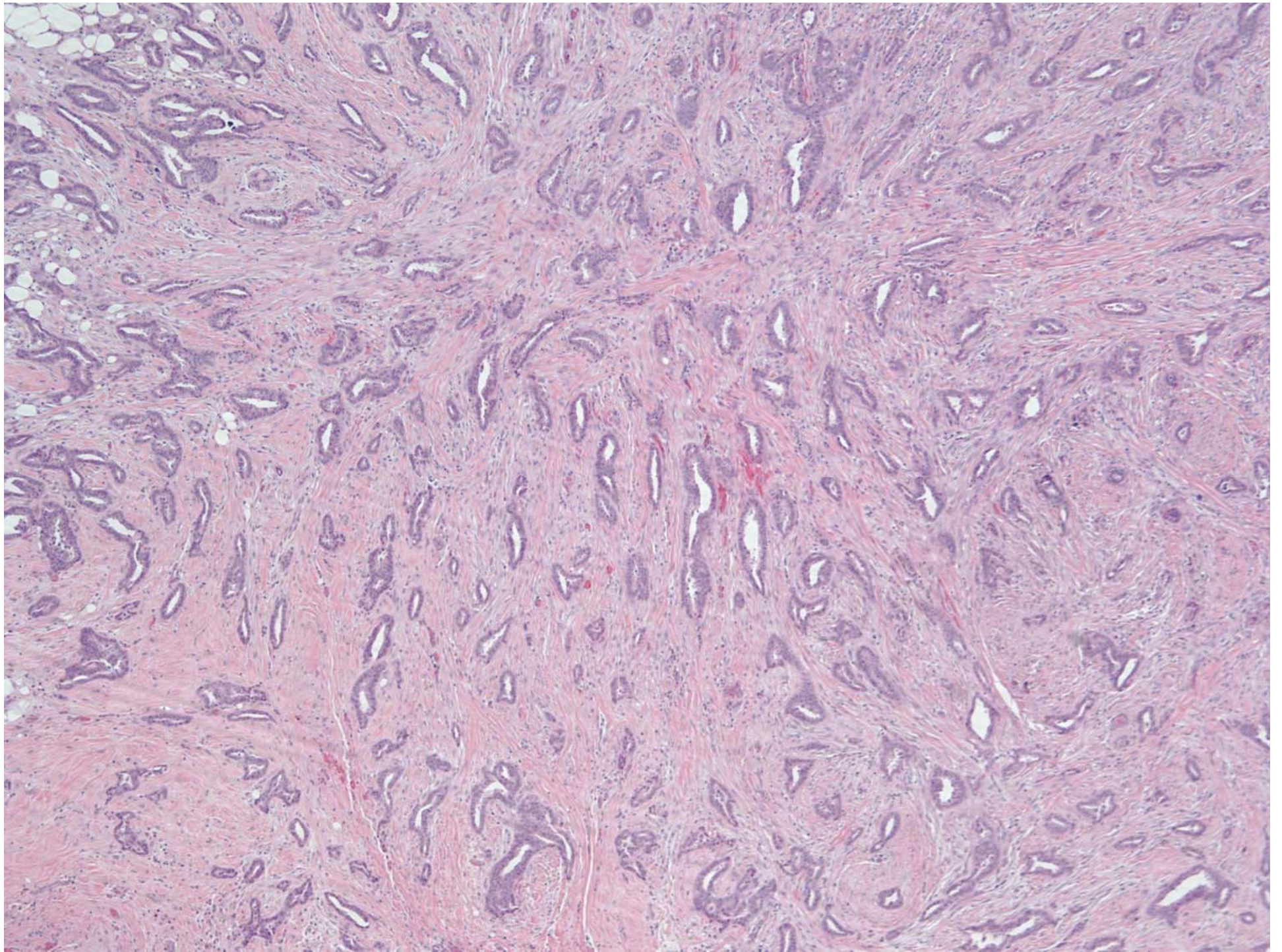


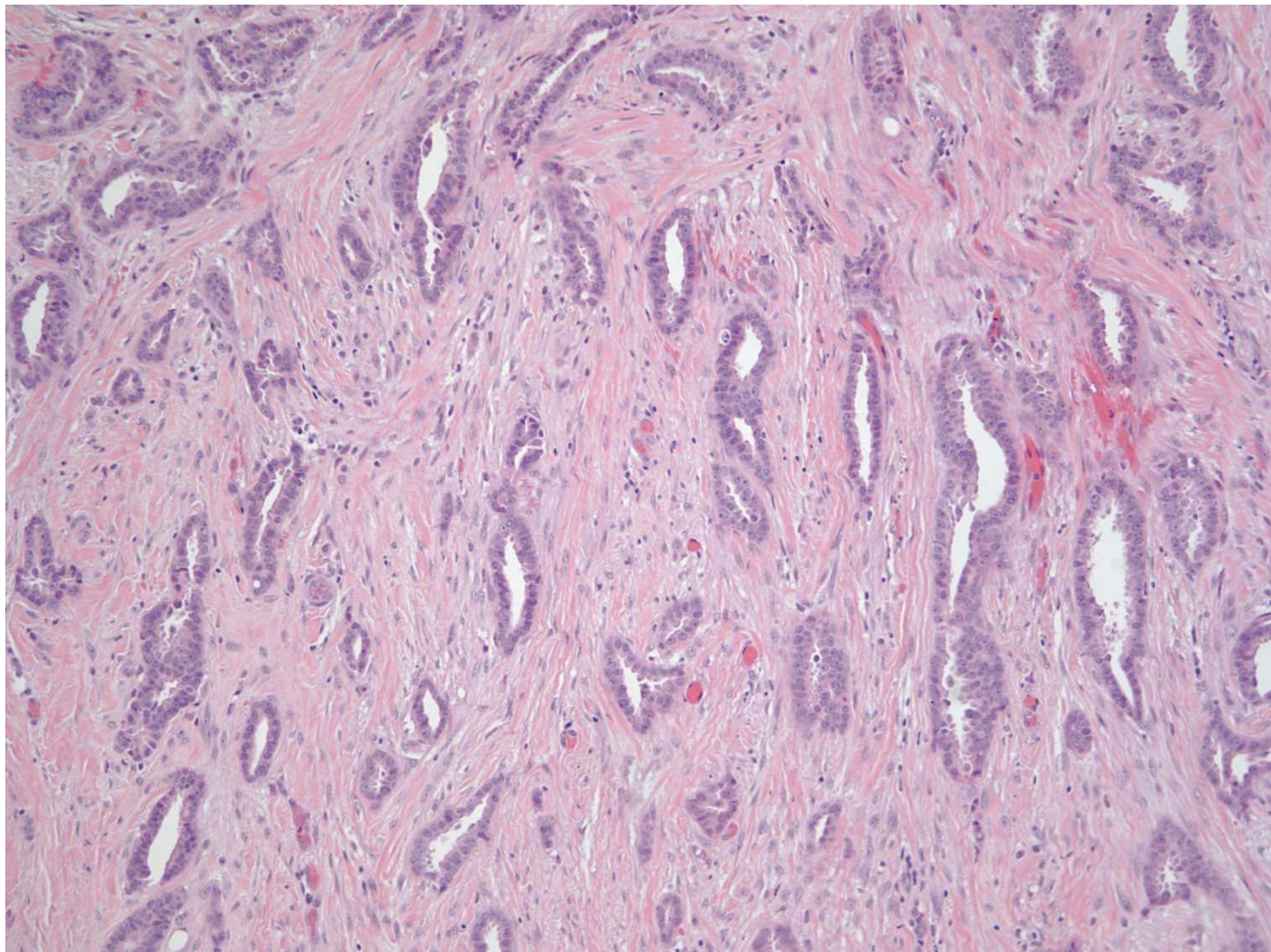
Take-home points:

- Correlate panel with histology!
- Low grade processes that are ER/HER2 negative:
 - Adenoid cystic carcinoma
 - Low grade metaplastic carcinomas (adenosquamous carcinomas, fibromatosis-like, etc)
 - Well differentiated apocrine carcinomas
 - Microglandular adenosis (not “invasion”?)
- Worth a comment in reports! Clinicians often treat all triple negative cancers the same

Case 6

65 year old with invasive breast
cancer





Pathology findings:

- Nottingham grade 1 invasive ductal/tubular carcinoma
- ER: Strong positive (>95%, 3+)
- PR: Positive (50-60%, 2+)
- HER2: Negative by IHC and FISH
- Ki67: 5-10%

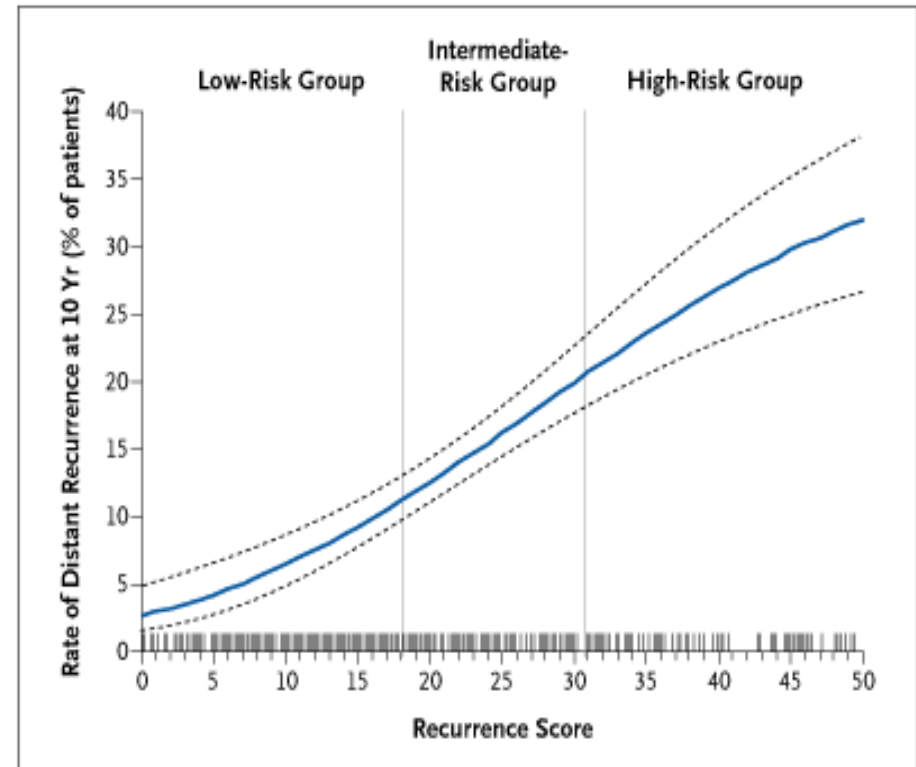
Oncologist requests a block be sent for OncotypeDX testing

Oncotype DX recurrence score:
34 (High)!!!

Why???

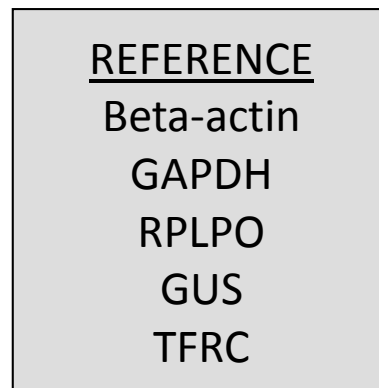
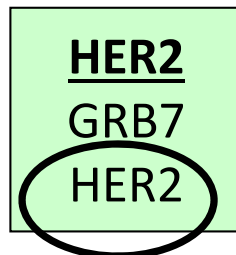
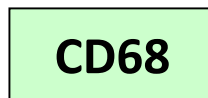
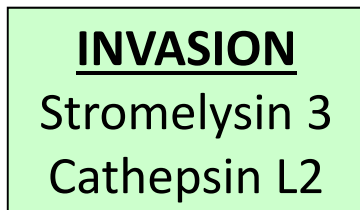
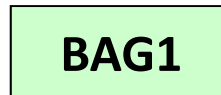
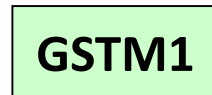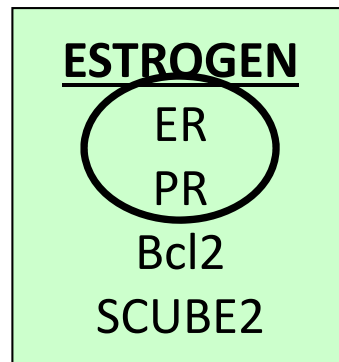
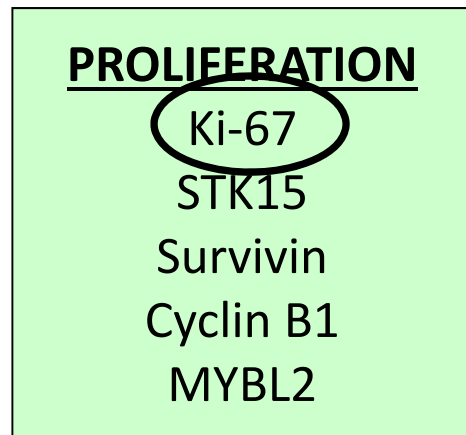
OncotypeDX Recurrence Score

- RT-PCR using 21 genes
- Predicts recurrence rates in ER+, lymph node negative patients
- Now also report quantitative ER, PR and Her2 mRNA levels



Calculating the RS

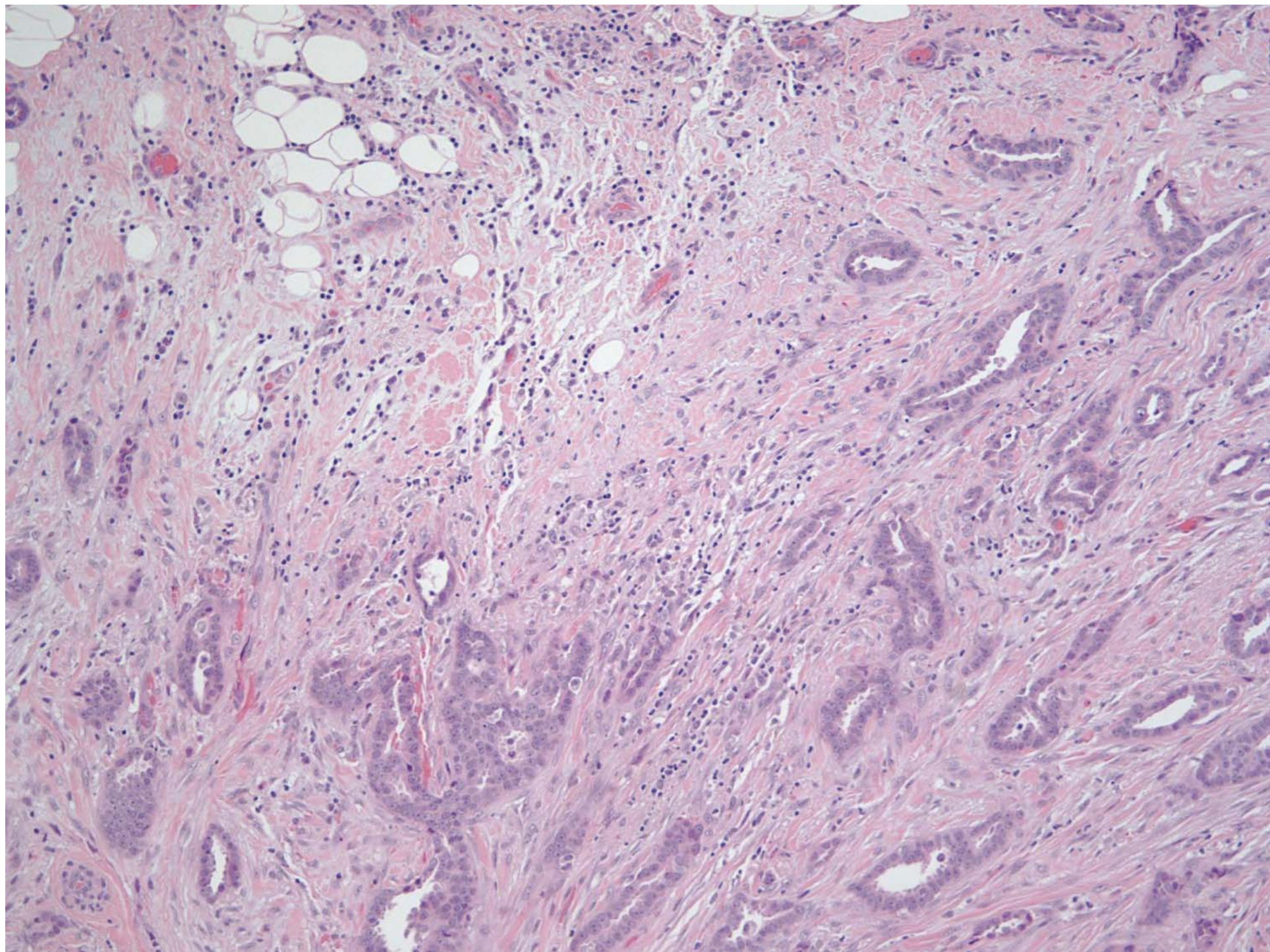
16 Cancer and 5 Reference Genes



$$\begin{aligned}
 \text{RS} = & + 0.47 \times \text{HER2 Group Score} \\
 & - 0.34 \times \text{ER Group Score} \\
 & + 1.04 \times \text{Proliferation Group Score} \\
 & + 0.10 \times \text{Invasion Group Score} \\
 & + 0.05 \times \text{CD68} \\
 & - 0.08 \times \text{GSTM1} \\
 & - 0.07 \times \text{BAG1}
 \end{aligned}$$

Category	RS (0-100)
Low risk	RS <18
Int risk	RS ≥18 and <31
High risk	RS ≥31

Paik et al. *N Engl J Med.* 2004;351:2817-2826.



Take home points:

- The pathologist needs to correlate Oncotype DX results with rest of the features of the case and be able to explain unexpected results or advise on testing
- When selecting blocks for testing try to avoid blocks with intermixed inflammation

Case 7

54 year old woman with a Grade 3
invasive ductal carcinoma. Her
oncologist asks you to explain
differences in reported ER results.

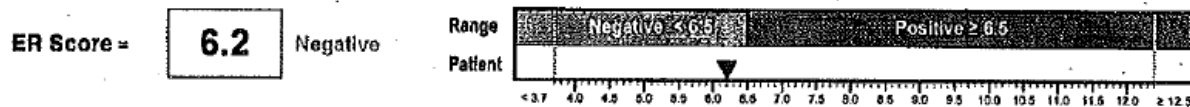
Summary of ER Results on Grade 3 IDC

- Core Biopsy outside read by image analysis : ER 2%
- Core biopsy by our review: 20%, 1+
- Excision at Stanford: 30%, 1-2+
- Oncotype DX: High RS (54; 34% recur)

Quantitative Single Gene Report

The Oncotype DX assay uses RT-PCR to determine the RNA expression of the genes below. These results may differ from ER, PR, or HER2 results reported using other methods or reported by other laboratories.¹

The ER, PR, and HER2 Scores are also included in the calculation of the Recurrence Score.



The ER Score positive/negative cut-off of 6.5 units was validated from a study of 761 samples using the 1D5 antibody (immunohistochemistry) and 607 samples using the SP1 antibody (immunohistochemistry). The standard deviation for the ER Score is less than 0.5 units.²

Clinical Experience:

For ER positive breast cancer, the magnitude of tamoxifen benefit increases as the ER Score increases from 6.5 to ≥12.5.³

Please note: The Average Rate of Distant Recurrence reported on Page 1 based on the Recurrence Score was determined in patients who received 5 years of tamoxifen treatment and takes into account the magnitude of tamoxifen benefit indicated by the ER Score.

Breast Cancer Assay Description

Oncotype DX Breast Cancer Assay uses RT-PCR to determine the expression of a panel of 21 genes in tumor tissue. The Recurrence Score[®] is calculated from the gene expression results. The Recurrence Score range is from 0-100.

**Breast Cancer
Recurrence Score** = **51**

The findings summarized in the Clinical Experience sections of this report are applicable to the patient populations defined in each section. It is unknown whether the findings apply to patients outside these criteria.

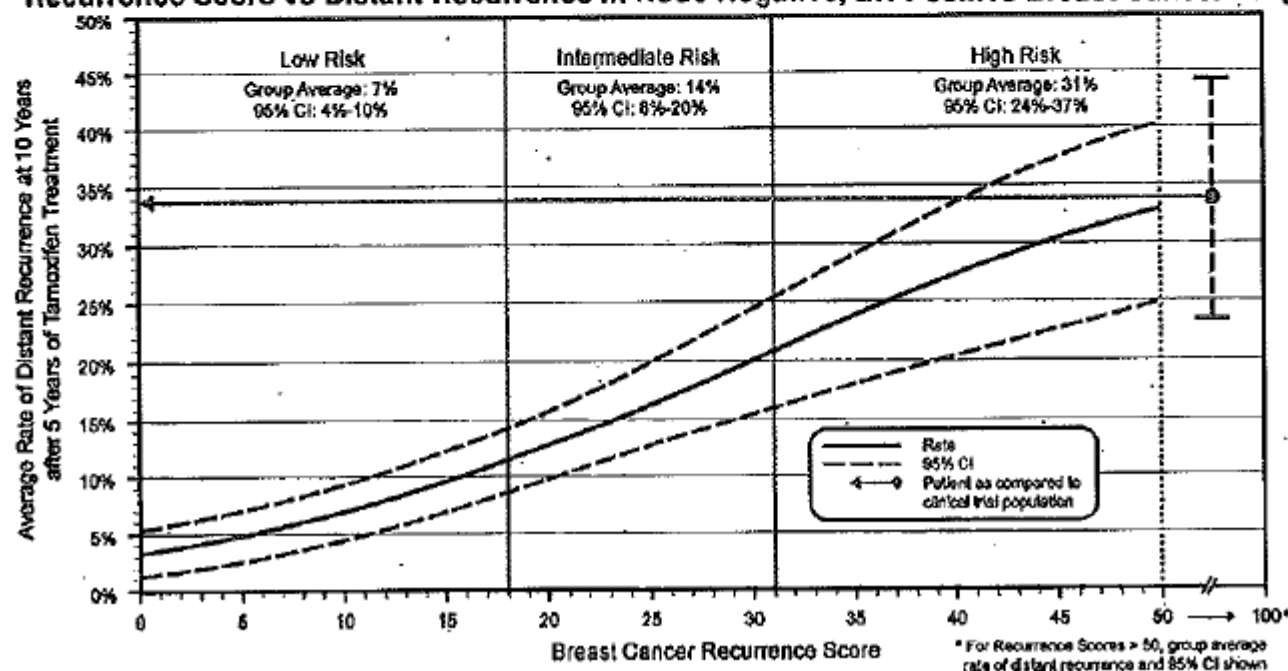
Clinical Experience: Prognosis for Node Negative, ER-Positive Patients

Oncotype DX RT-PCR analysis of ER expression indicates this specimen is ER negative.
The specimen must be ER positive by RT-PCR or IHC for the Recurrence Score Clinical Experience to apply.

The Clinical Validation study included female patients with Stage I or II, Node Negative, ER-Positive breast cancer treated with 5 years of tamoxifen. Those patients who had a Recurrence Score of > 50 had an Average Rate of Distant Recurrence of **34% (95% CI: 23%-44%)**

The following results are from a clinical validation study of 668 patients from the NSABP B-14 study. *N Engl J Med* 2004; 351: 2817-26.

Recurrence Score vs Distant Recurrence in Node Negative, ER-Positive Breast Cancer Prognosis



Node Negative

How do you explain the different results?

1. Heterogeneity for ER expression/different samples used
2. Differences in assay techniques
3. Differences in interpretation techniques
4. Error
5. Other

Final Take-Home Points

- Know your guidelines
- Know something about ancillary testing techniques even if you don't perform them yourself
- Recognizing discordant ancillary test results and when to repeat or offer additional testing
- Be able to explaining apparent discrepant results to clinical teams and advise on management decisions relating to ancillary test results